

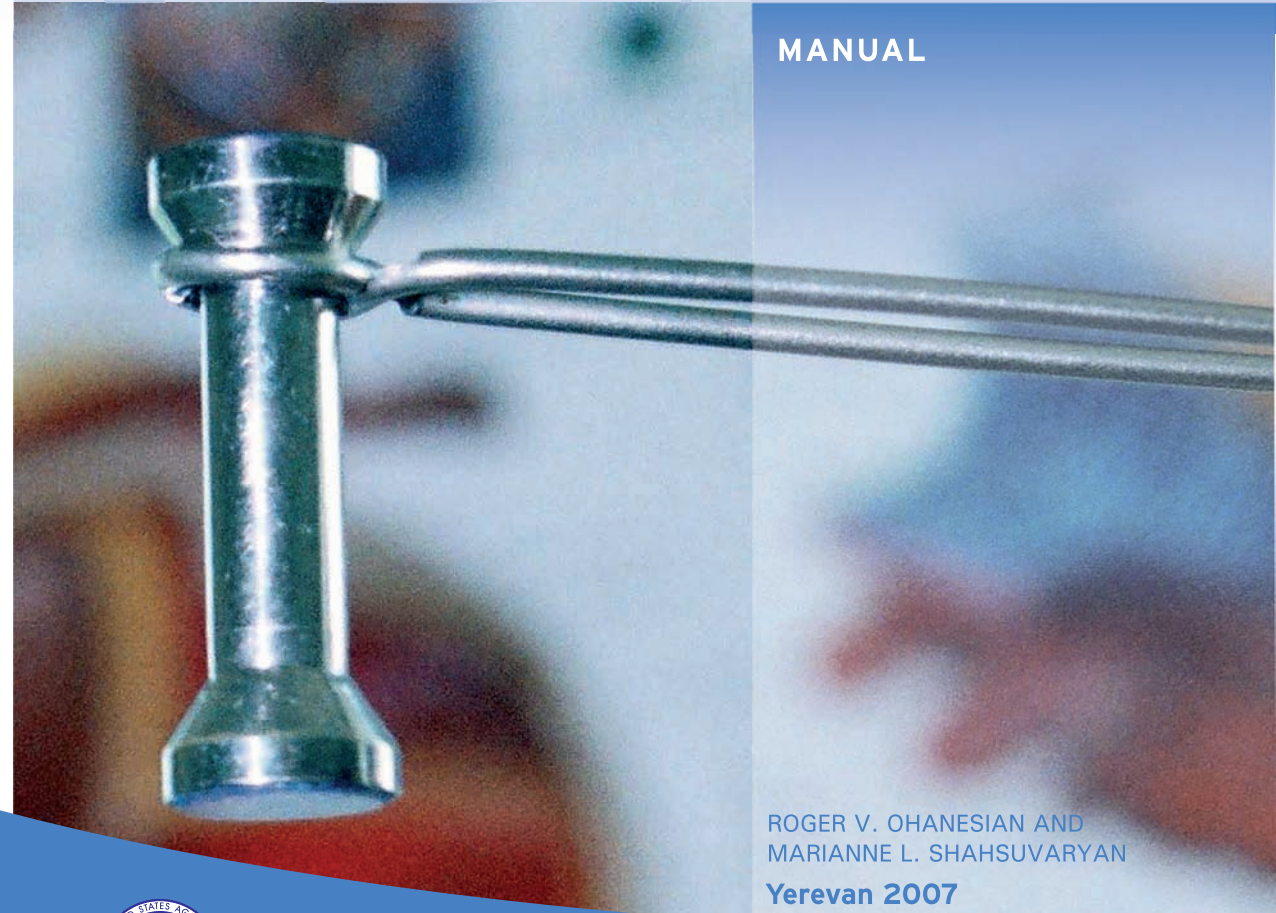
Yerevan
2007

ROGER V. OHANESIAN AND
MARIANNE L. SHAHSUVARYAN

Essentials of Ophthalmology

Essentials of Ophthalmology

MANUAL



ROGER V. OHANESIAN AND
MARIANNE L. SHAHSUVARYAN
Yerevan 2007

www.eyecareproject.com



USAID
FROM THE AMERICAN PEOPLE



aecpp the armenian eyecare project



5 Aygestan str, house 7, Yerevan 0025, Armenia
phone: (+374-10) 55-90-68, fax: (+374-10) 57-76-94

P.O. Box 5630, Newport Beach California 92662-5630, USA
phone: 949-675-5767, fax: 949-673-2356



USAID
FROM THE AMERICAN PEOPLE



aecpp the armenian eyecare project



USAID
FROM THE AMERICAN PEOPLE



THE ARMENIAN
EYECARE
PROJECT

ROGER V. OHANESIAN MARIANNE L. SHAHSUVARYAN

ESSENTIALS OF OPHTHALMOLOGY

MANUAL

YEREVAN
“Na Da Ma” LLC
2007

ACKNOWLEDGMENTS

AUTHORS WOULD LIKE TO EXPRESS THEIR HEARTFELT APPRECIATION AND SINCERE GRATITUDE TO THE SCIENTIFIC ADVISOR OF PRESENT MANUAL, PROFESSOR **ALEXANDER MALAYAN**, MD, PhD, DSc, MEDICAL DIRECTOR OF ARMENIAN EYE CARE PROJECT (AECF).

Authors would like to thank the Republic of Armenia Ministry of Health. Authors express their deep gratitude to the reviewers of present Manual – professor Levon Barseghyan, MD, PhD, DSc, professor Alla Hovhannisyan, MD, PhD, DSc, and professor Armen Shakaryan, MD, PhD, DSc. Authors are appreciative of the AECF Program Committee members and AECF Fellows.

Authors would like to thank all the AECF staff in the person of AECF Armenian Office Director Nune Yeghiazaryan for their constant support. Authors express their sincere gratitude to Stephanie Russin for her assistance in editing the manuscript.

Manual is approved by the RoA Ministry of Health

ՀՏԴ 617.7 (07)

ԳՄԴ 56.7 գ7

Օ 451

- Օ 451 Roger Ohanesian, Marianne Shahsuvaryan
Essentials of Ophthalmology; Manual for ophthalmologists, residents and medical students. Yerevan "NADAMA" LLC; 2007 - 234pp.

ԳՄԴ 56.7 գ7

ISBN 978 - 99941 - 818 - 1 - 0

© The Armenian Eyecare Project, 2007



TABLE OF CONTENTS

▲ 1. THE EYE EXAMINATION	8
1.1 Preliminary Ocular And Medical History	8
1.2 The Pinhole Acuity Test	9
1.3 Cover- Uncover Test.....	10
1.4. Ocular Motility Testing	11
1.5. Confrontation Field Test.....	12
1.6. Red Differentiation Test	13
1.7. The Amsler Grid Test	13
1.8. The Anterior Chamber Depth Assessment	14
1.9. The Afferent Pupillary Defect.....	14
1.10. Optical Coherence Tomography (OCT)	15
▲ 2. EYE LID/ORBIT.....	17
2.1. Blepharitis And Meibomitis.....	17
Staphylococcal.....	17
Seborheic.....	18
Demodectic.....	18
2.2. Cellulitis	20
Preseptal Cellulitis	20
2.3. Orbital Cellulitis.....	22
▲ 3. CONJUNCTIVA/CORNEA	26
3.1. Allergic Conjunctivitis.....	26
3.2. Viral Conjunctivitis	27
3.3. Vernal Conjunctivitis (VC)	30
3.4. Dry Eye Syndrome.....	32
3.5. Corneal Abrasion	36
3.6. Bacterial Corneal Keratitis (Corneal Ulcer	37
3.7. Herpetic Keratitis	39
3.8. Herpes Zoster Ophthalmicus.....	44
▲ 4. SCLERA/UVEA	47
4.1. Anterior Uveitis (Iritis/Iridocyclitis).....	47

4.2. Posterior Uveitis	55
4.2.1. Ocular toxoplasmosis	55
4.2.2. Behcet's disease	59
4.2.3. Sympathetic ophthalmia	62
▲ 5. LENS	65
5.1. Congenital Cataract	65
5.2. Acquired Cataract	68
Age-related.....	68
Drug-Induced, Toxic (Steroids, anticholinesterases (miotics), antipsychotics (phenothiazines), amidarone, chemicals.....	68
5.3. Pseudoexfoliation Syndrome	72
5.4. Traumatic Lens Subluxation And Dislocation	73
5.5. Management And Treatment In Acquired Cataract.....	74
5.6. Cataract Surgery Timing	75
5.7. Lens-Induced Secondary Glaucoma.....	75
5.8. Anesthesia For Cataract Surgery	78
5.9. TECHNIQUES FOR CATARACT SURGERY	81
5.10. POSTOPERATIVE CARE	83
5.11. Postoperative Complications.....	84
5.12. Posterior Capsular Opacification (Pco)	85
5.13. Cataract: Points To Remember	86
▲ 6. VITREOUS	87
6.1. Vitreous Hemorrhage	87
6.2. Posterior Vitreous Detachment (Pvd).....	91
▲ 7. OPTIC NERVE	95
7.1. Anterior Ischemic Optic Neuropathy (AION)	95
7.2. Posterior Ischemic Optic Neuropathy (Pion)	98
▲ 8. RETINA - VASCULAR OCCLUSIONS.....	99
8.1. Central Retinal Artery Occlusion (CRAO).....	99
8.2. Central / Hemiretinal Vein Occlusion (CRVO/HRVO)	102
8.3. Branch Retinal Vein Occlusion (BRVO)	107
▲ 9. MACULA	111
9.1. Age-Related Macular Degeneration (Amd)	111
9.2. Nonexudative (Dry) Macular Degeneration	113

9.3. Exudative (Wet) Macular Degeneration	114
9.4. Central Serous Chorioretinopathy	117
9.5. Cystoid Macular Edema	120
▲ 10. RETINA.....	124
10.1. Retinal Detachment (RD).....	124
10.2. Rhegmatogenous Retinal Detachment Due To Retinal Tear - Primary RD.....	125
10.3. Secondary Detachments - Tractional RD And Exudative RD	127
▲ 11. OCULAR MANIFESTATIONS OF SYSTEMIC DISEASE	130
11.1. Diabetic Retinopathy (DR).....	130
11.2. Hypertensive Retinopathy	138
▲ 12. GLAUCOMA	140
12.1. Primary Open-Angle Glaucoma	140
12.2. Normal (Low) Tension Glaucoma.....	146
12.3. Primary Angle-Closure Glaucoma	148
12.4. Neovascular Glaucoma.....	152
▲ 13. PEDIATRIC OPHTHALMOLOGY	154
13.1. Retinopathy Of Prematurity (ROP).....	154
13.2. Strabismus	157
13.3. Amblyopia	166
13.4. Congenital Nasolacrimal Duct Obstruction.....	168
▲ 14. TRUE OCULAR EMERGENCY	171
14.1. Chemical or Thermal Burn	171
14.2. Central Retinal Artery Occlusion (CRAO).....	173
14.3. Primary Angle-Closure Glaucoma	177
▲ 15. ENDOPHTHALMITIS	182
▲ 16. POSTOPERATIVE CARE AFTER CATARACT SURGERY	188
▲ 17. BLIND, PAINFUL EYE	193

▲	18. OCULAR PHARMACOLOGY	195
▲	19. DIAGNOSTIC FLOW SHEETS.....	201
	19.1. Painful and Painless Red Eye	201
	19.2. Red Eye with and without Vision Loss	203
	19.3. The Red Eye Differential Diagnosis	205
	19.4. Differential Diagnosis of Conjunctivitis	207
	19.5. Acute Vision Loss	209
	19.6. Gradual Vision Loss over hours to day	211
	19.7. Gradual Vision Loss over days to months	213
	19.8. Vision Loss	215
	19.9. Co-existing Eye Disease in Cataract Patients.....	219
	19.10. Double Vision.....	221
	19.11. Signs/Symptoms of Complications after Ocular Surgery.....	223
▲	APPENDIX:.....	225
	CLINICAL SKILLS	225
▲	INDEX.....	230
▲	ANNOTATED RESOURCES	234



PREFACE

The doubling time of information in medicine and specifically in ophthalmology is estimated by some to be less than two and a half years. This ongoing explosion of knowledge has not been ignored by the professions involved in the care of the eye and its disease.

We believe it is time to provide the practicing ophthalmologist, resident, and medical student with an easy-to-read, comprehensive ophthalmology manual.

The purpose of this book is twofold: to present concise, useful information on a broad range of ophthalmic disorders and to direct this information to a wide audience.

We have organized the book into sections corresponding to each ocular structure and the different aspects of a routine eye examination.

Each chapter is further subdivided into the classical pathological rubric of symptoms - signs - etiology- differential diagnosis - treatment - follow-up. This allows the pertinent diagnostic information on any given disorder to be quickly and easily accessed. We have used an outline format to include all essential data for making a diagnosis and properly managing most common ophthalmic disorders.

We include POINTS to REMEMBER reflecting pitfalls and presenting practical tips for avoiding or resolving common problems in certain subject areas.

At the same time, the diagnosis and treatment of eye disease is visually oriented, a circumstance most appropriate to the organ of vision. In reality, we can visualize with our own eyes many changes that occur in the eyes of our patients. Thus, the written text alone is an inadequate medium to convey the necessary information about the diseases that affect the human eye. We decided to expand the text with color photos to enhance its usefulness to the reader.

We hope that this book will serve as a practical review guide for all ophthalmologists in providing patients with the best care possible. ▲



1. THE EYE EXAMINATION



1.1. PRELIMINARY OCULAR AND MEDICAL HISTORY

Chief Complaints

What are your symptoms?

- ▼ One eye or both?
- ▼ When did the problem start?
- ▼ Does the problem seem to be getting worse?

Any associations

- ▼ Since trauma
- ▼ Since surgery (of blood vessel, brain, heart, kidney)
- ▼ With meals

ADD QUESTIONS

1. **Status of vision:** Have both the near and far vision been affected?
Has the vision been affected in one eye or both?
2. **Onset:** Did the problem start suddenly or gradually?
3. **Presence:** Are the symptoms constant or occasional, frequent or infrequent? Does a specific activity trigger the symptoms or make them worse?
4. **Progression:** has the problem become better or worse over time?
5. **Severity:** Do the symptoms interfere with your work or other activities?
6. **Treatment:** Have you ever been treated for these complaints?

OCULAR HISTORY

(Present to past)

- ▲ Do you wear, or have you ever worn eyeglasses or contact lenses?
- ▲ Have you ever had eye surgery?
- ▲ Have you ever been treated for a serious eye condition?
- ▲ Are you taking any prescription or over-the-counter medications for your eyes, including eye-drops?

MEDICAL HISTORY

(Present to past)

- ▲ Are you taking any prescription or over-the-counter medications for a health condition?
- ▲ Have you ever required treatment for any serious disease? (Ask specifically about diabetes and hypertension).

FAMILY OCULAR AND MEDICAL HISTORY?

- ▲ Does anyone in your family have any significant eye or other health problems?
(glaucoma, cataract, diabetes, heart disease, hypertension, cancer).
Allergies
- ▲ Do you have any allergies to medication, pollen, food or anything else?

1.2. THE PINHOLE ACUITY TEST

Patients who wear corrective eyeglasses or contact lenses should wear them for the test. Position the patient as for the Snellen distance acuity test, and test each eye separately, starting with the right eye. ▼

1. Have the patient cover the eye not being tested with an occluder or the palm of the hand. Alternatively, you may hold the occluder over the patient's eye. (Fig.1.1A)
2. Have the patient hold the pinhole paddle in front of the eye that is to be tested. (Fig. 1.1.B).
3. Instruct the patient to look at the distance chart through the pinhole (or through any of the pinholes on a multi-hole paddle).

4. Instruct the patient to use very small movements to align the pinhole to produce the sharpest image.
5. Ask the patients to begin reading the line with the smallest letters legible without the pinhole, just as is done for the Snellen distance acuity chart.
6. Repeat steps 1 through 5 for the other eye.
7. Following the Snellen visual acuity data already recorded in the chart, record the pinhole acuity value for each eye. In the example that follows, ph = pinhole.

OD 20/80 20/20^{ph}
OS 20/100 20/25^{ph}



A
Fig. 1.1 The pinhole acuity test

B

1.3. COVER- UNCOVER TEST

This test distinguishes between a tropia and a phoria. The patient fixates on a target and an occluder is placed in front of the eye. One eye is covered and then uncovered. If the unoccluded eye moves when the cover is in place, a tropia is present. If the covered eye moves when the cover is removed, a phoria is present (Fig. 1.2).

The position of the light reflex upon the iris as an indicator of phoria/ tropia. If when the light is projected upon the eyes from a near position and the light is within the pupil and when there is movement when doing the cover/ uncover test, then it will be a phoria.

If when the reflex falls outside the pupil on one of the eyes for the near

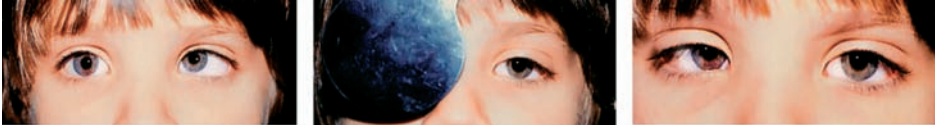

Fig.1.2 Cover/Uncover test

light test, then it is a tropia. If the eye that has the abnormal reflex also has reduced best corrected vision then they have amblyopia. If when they have an offcenter reflex during cover uncover they may also have abnormal retinal correspondence.

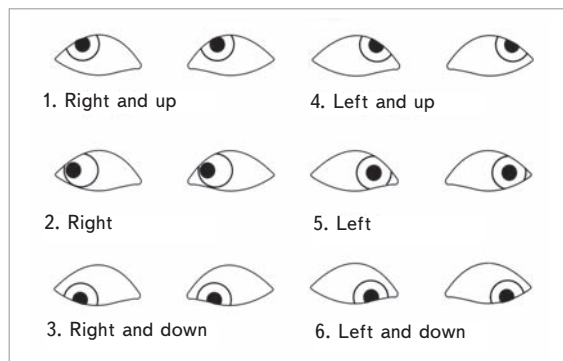
It is also wise to check for distance phoria by the cover uncover as was described.

As a general rule, myopes have esophoria/tropia for distance, while hyperopes have more exotropia at near. Hypertropes develop more exophoria/tropia as they age making concentration while reading more difficult due to progressive clarity diminishing to blurred ghosting then to frank diplopia. It should always be considered for hyperopic patients who complain of difficulty reading with their current pair of glasses. ▼

1.4 OCULAR MOTILITY TESTING

For the evaluation of ocular motility, the examiner holds a small object or displays a finger within the patient's central field of vision and asks the patient to follow its movement with the eyes in the six cardinal positions of gaze (Fig. 1.3).

Fig.1.3 Ocular motility Testing
The patient follows movements of small object or a finger in the six cardinal positions of the gaze.



1. 5 CONFRONTATION FIELD TEST

The confrontation field test compares the boundaries of the patient's field vision with that of the examiner, who is presumed to have a normal field. This procedure is carried out as follows:

1. Seat the patient at a distance of 2 to 3 feet from you. Confront (face) the patient, cover or close your left eye, and have the patient fixate on your uncovered eye.
2. Extend your arm to the side at shoulder height and slowly bring two fingers from beyond your peripheral vision toward your nose into the field of vision midway between the patient and yourself. Ask the patient to state when the fingers are visible.(Fig. 1.4)
3. Repeat the process of moving your fingers into the visual field from four different directions. If you picture a clock face in front of the patient's eyes, you perform the hand movement at approximately 2 o'clock, 4 o'clock, 8 o'clock, and 10 o'clock, each time bringing the fingers toward the center of the clock face.
4. The patient should see the fingers at about the same moment you do in each of the four quadrants (upper-left, upper-right, lower-right quarters) of the visual field. (Note: A quadrant of vision is described from the patient's point of view). If the patient does not see your fingers at the same time you do, the breadth of the patient's visual field in that quadrant is considered to be smaller than normal and additional parametric studies will probably be required.
5. Record the patient's responses in the patient's chart by indicating simply that the visual field is comparable to yours (normal) or that it is reduced in any of the four quadrants for that eye.
6. Repeat the procedure with the patient's other eye and similarly record the results. ▼



Fig. 1.4 Confrontation Field Test

1.6 RED DIFFERENTIATION TEST


Red differentiation is a way to determine macular degeneration of an eye. Ask the patient if the saturation of red is different in one eye compared to the other. If one eye is only 50% of the other it is recorded and is a gross measurement of macular function. It alerts the examiner to the possibility of macular degeneration. ▼

1.7 THE AMSLER GRID TEST

1. Have the patient hold a white-on-black test card about 16 inches away with one hand and cover one eye with the other hand and an occluder, or a patch. (Fig. 1.5)
2. Direct the patient to stare at the center dot and to report if any portions of the grid are blurred, distorted, or absent. The patient should not move the gaze from the center dot, so that the presence of any distortion can be assessed.
3. If the answer is yes, you may repeat the test with a black-on-white Amsler recording chart, on which you ask the patient to mark the location of visual difficulties.
4. If the test results are normal, state so in the patient's record. If abnormal, state so and include the Amsler recording chart in the patient's record. If visual disturbances are noted, the patient is a likely candidate for further studies.

The patient may repeat this convenient procedure independently at home and report any changes to the ophthalmologist's office. Instruct the patient to perform the test monocularly (one eye at a time), always at the same 16-inch distance and under the same illumination. ▼

Fig. 1.5 The Amsler grid test



1. 8 THE ANTERIOR CHAMBER DEPTH ASSESSMENT

1. Hold a penlight near the limbus of the right eye from the temporal side of the patient.
2. With the penlight parallel to the plane of a normal iris, shine the light across the front of the patient's right eye toward the nose.
3. Observe the appearance of the iris closest to the patient nose. In an eye with a normally shaped anterior chamber and iris, the nasal half of the iris will be illuminated like the temporal half (Fig.1.6). In an eye with a shallow anterior chamber and narrow chamber angle, about two thirds of the nasal portion of the abnormally curved iris will appear in shadow. (Fig.1.7)
4. Record your observations in the patient record and repeat the test on the patient's left eye. Consult the physician for the appropriate way to express your observations in the chart. ▼

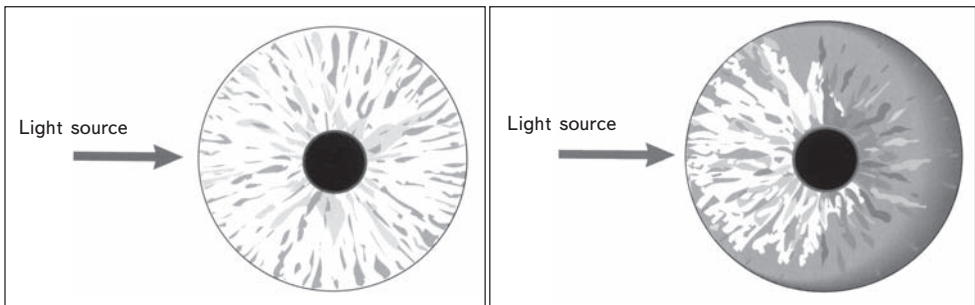


Fig.1.6 Open anterior chamber angle

Fig.1.7 Narrow anterior chamber angle

1.9 THE AFFERENT PUPILLARY DEFECT

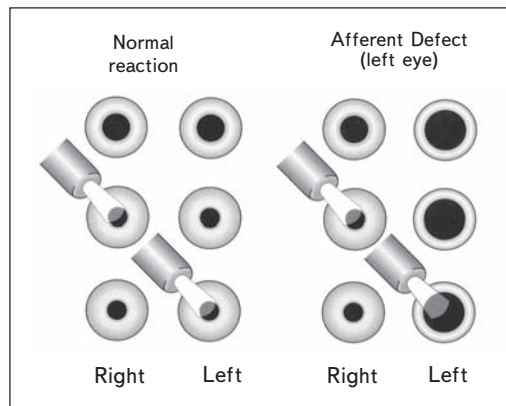
1. Seated opposite the patient in ordinary room light, observe the patient's resting pupil size for both the right and the left eyes. Both pupils should be dilated equally (Fig. 1.8).
2. In the patient's chart, record the resting pupil size for each eye in millimeters. To gauge size, you may either hold a millimeter rule close to the patient's eye or compare the patient's pupil size with relative pupil sizes printed on most near vision cards.
3. As shown in Fig. 1.8, shine a penlight (a small flashlight) into the patient's right eye and observe if the pupil constricts in response to

the direct light stimulus. Look immediately at the left pupil to see if it constricts consensually.

4. Remove the penlight from the patient's vision briefly to allow the pupils to return to resting state and then repeat step 3 for the left eye.
5. In the patient's chart, record the results for each eye. If the results are normal, record "Reactive to light, direct and consensual"; if the results are abnormal, record either "No direct response" or "No consensual response" whichever applies.
6. The penlight beam is moved from the right eye to the left eye, the pupil of the left eye may continue to dilate instead of stay constricted due to consensual reaction. This is an afferent pupillary defect. ▼

Fig. 1.8

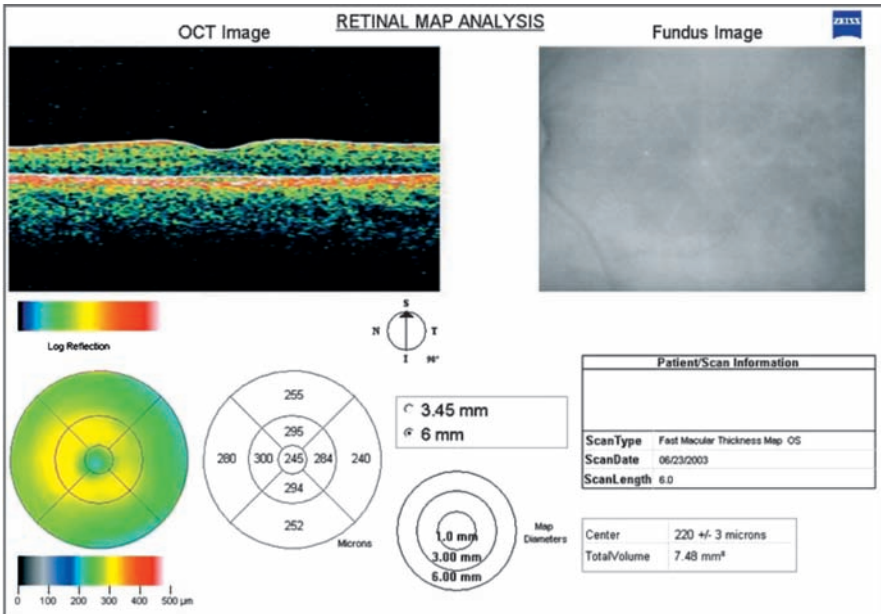
Pupillary reflexes. The Afferent pupillary defect. The penlight beam is moved from the right eye to the left eye, the pupil of the left eye may continue to dilate instead of stay constricted due to consensual reaction.



1.10 OPTICAL COHERENCE TOMOGRAPHY (OCT)

OCT obtains images by using back scattering of light in a similar way to ultrasound B scanning but as the wavelength of light is shorter the resolution is much higher. OCT uses a low-coherence infrared beam producing a depth-specific signal corresponding to the tissue reflectivity at that point. The degree of reflectivity is displayed in false color giving an "anatomical" display (Fig 1.9).

OCT has become essential in the clinical evaluation of macular pathology such as macular hole, cystoid edema, pigment epithelial detachment and preretinal membranes, and the demonstration of vitreous traction. Future developments of OCT show great potential for measuring optic disc cupping and nerve fiber layer thickness in glaucoma. Recently a new OCT has been developed for anterior segment imaging which is likely to be of great benefit in identifying the AC for phakic IOL. ▼



© 2005 Elsevier Ltd. Spalton et al: Atlas of Clinical Ophthalmology 3e

Fig.1.9 Optical Coherence Tomography (OCT)

2. EYE LID/ORBIT DISEASES

2.1 BLEPHARITIS AND MEIBOMITIS

Inflammation of the eyelid margins (blepharitis) (Fig 2.1) and inspissation of the oil-producing sebaceous glands of the lids (meibomitis) (Fig 2.2); often occur together; this is extremely common in the adult population and often coexist with dry eyes.

ETIOLOGY

Chronic Staphylococcus or Demodex infection, seborrhea, eczema; angular blepharitis is associated with Moraxella infection..

SYMPTOMS:

- Itching
- Red eye
- Burning
- Tearing
- Mild pain
- Foreign body sensation
- Often worse on awakening and late in the day.

SIGNS:

- Thickened and erythematous eyelid margins with teleangiectatic blood vessels, crusting along eyelashes (“scurf” and “collarettes” in blepharitis);
- swollen, pitted or blocked meibomian glands (meibomitis);
- may have “toothpaste sign” (gentle pressure on lids expresses columns of thick, white sebaceous material from meibomian gland)

DIFFERENTIAL DIAGNOSIS

STAPHYLOCOCCAL blepharitis is a common condition typified by the presence of inflamed lid margin, purulent discharge (Fig 2.3).

In **SEBORRHEIC** blepharitis dandruff-like flakes (“scurf”) or amorphous accumulations of oily sebaceous material, or both, are found randomly distributed on and among the eyelashes (Fig 2.4). Meibomitis and meibomian dysfunction are also forms of seborrheic blepharitis but occur in the posterior eyelid.

DEMODECTIC blepharitis is caused by infestation of the eyelash follicles with a mite, *Demodex folliculorum* (Fig 2.5), and is especially common in elderly patients (Fig. 2.6). This form of blepharitis is actually associated with little or no inflammation and is thought generally to be asymptomatic unless the population of organisms become elevated and therefore may be the cause of frequent chalazia, hordeoli or madreosis. It is typified by the presence of waxy, cylindrical cuffs or “sleeves” around the bases of the eyelashes. Fig 2.7 diagrammatically depicts the difference in appearance between eyelashes collar-ettes, seborrheic eyelash scurf and eyelash sleeves.

The following signs are most often associated with long-standing staphylococcal blepharitis:

- ▲ Madarosis (loss of eyelashes)
- ▲ Peliosis (whitening of eyelashes)
- ▲ Trichiasis

MANAGEMENT

- ▲ Warm compresses for 10 minutes in both eyes qd to qid
- ▲ Daily lid scrubs: a warm solution of baby shampoo and water (50:50 mixture) may be applied rigorously to the lids and lashes using cotton, a fine cloth or cotton-tipped applicator.
- ▲ Topical antibiotic ointment (Erythromycin) at bedtime for 1-2 weeks.

IF SEVERE:

- ▲ Consider short course (1-2 weeks) of topical antibiotic-steroid ointment (Tobradex) bid.
- ▲ Consider Doxycycline 50-100 mg po qd for recalcitrant cases.
- ▲ Treat associated pathology such as rosacea or dry eye.

PROGNOSIS

Good; recurrence common; maintenance treatment often required indefinitely. ▼

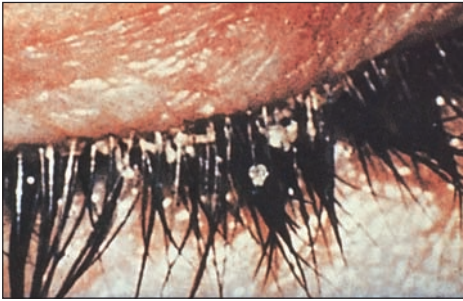


Fig. 2.1 Blepharitis

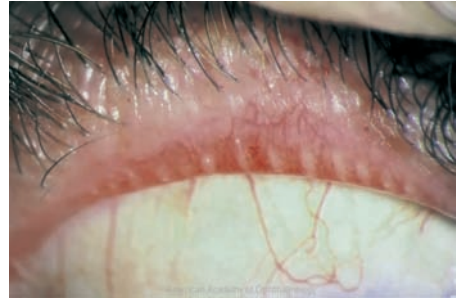

Fig. 2.2 Meibomitis

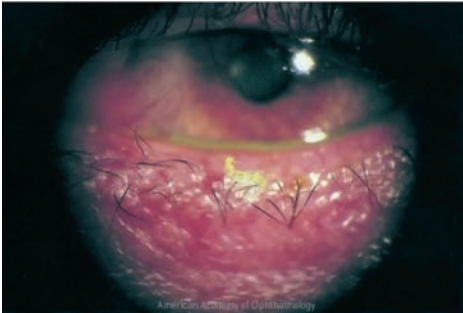

Fig. 2.3 Blepharitis Staphylococcal

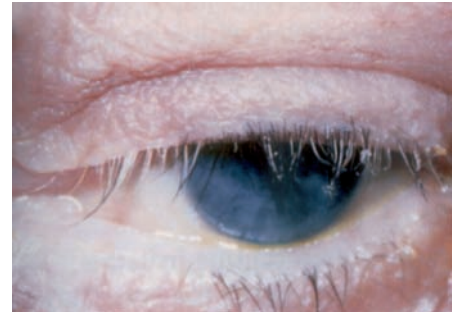


Fig. 2.4 Blepharitis seborrheic

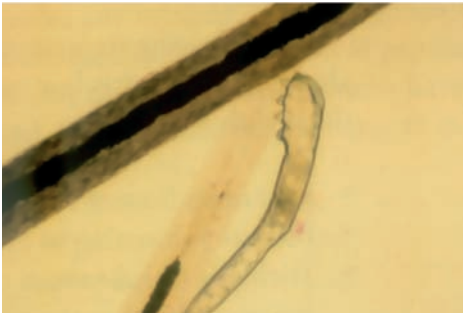

Fig. 2.5 Demodex folliculorum mite near epilated eyelash from a patient with demodectic blepharitis

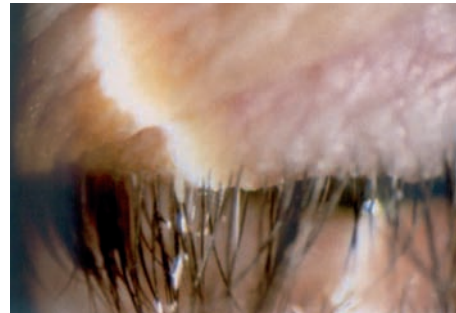


Fig. 2.6 Blepharitis demodectic. Sleeve or cuff in demodectic blepharitis (base of eyelash, just to left of where slit-lamp beam contacts skin of eyelid)

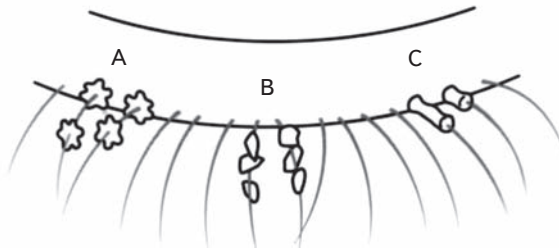


Fig. 2.7 Diagrammatic representations of lash collarettes (left), seborrhetic material (center), and lash sleeve

2.2 PRESEPTAL CELLULITIS

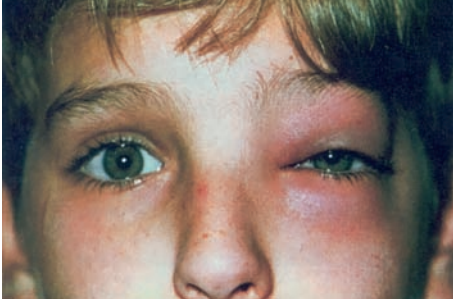

Fig. 2.8 Preseptal Cellulitis

Infection and inflammation located anterior to the orbital septum and limited to the superficial periorbital tissues and eyelid tissues and eyelids (Fig 2.8). The globe and orbit are not involved.

ETIOLOGY

Spread of infection from localized hordeola, contiguous infection from sinuses associated with upper respiratory tract infection, or trauma. One should suspect *Staphylococcus aureus* in traumatic cases, or *Haemophilus influenzae* in children less than 5 years old.

SYMPTOMS:

- Eyelid swelling
- Redness
- Ptosis
- Pain
- Low-grade fever

SIGNS:

- Eyelid erythema, edema, ptosis
- Warmth (may be quite dramatic)
- Visual acuity is normal when lid is elevated
- Full ocular motility without pain
- No proptosis
- The conjunctiva and sclera appear uninfamed
- An inconspicuous lid wound may be visible

DIFFERENTIAL DIAGNOSIS

Orbital cellulitis, eyelid abscess, dacryoadenitis, dacryocystitis, conjunctivitis, trauma, rhabdomyosarcoma (in children).

WORK-UP

- ▲ Complete ophthalmic history with attention to trauma, sinus disease, recent dental work or infections, history of diabetes or immunosuppression.
- ▲ Complete eye examination with attention to acuity, color vision, pupils, motility, exophthalmometry, lids, conjunctiva and sclera.
- ▲ Check vital signs, head and neck lymph nodes, meningeal signs (nuchal rigidity) and sensorium.
- ▲ Lab tests: complete blood count (CBC) with differential, blood cultures; take a culture if appropriate.

MANAGEMENT

MILD PRESEPTAL CELLULITIS

- ▲ Systemic oral antibiotics:
Amoxicillin-clavulanate (Augmentin) 250-500 mg po tid, or
Cefaclor 250-500 mg po tid, or
Bactrim 1 double-strength tablet po bid in penicillin-allergic patients
- ▲ Warm compresses tid
- ▲ Topical antibiotics (Erythromycin ointment qid) for concurrent conjunctivitis.
- ▲ Consider surgical drainage of abscess.

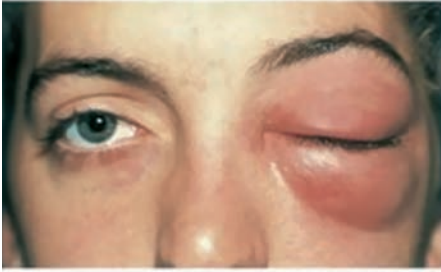MODERATE TO SEVERE PRESEPTAL CELLULITIS

- ▲ Systemic intravenous antibiotics
Cefuroxime 1g IV q.8h
- ▲ Systemic intravenous treatment also indicated for septic patients, outpatient non-compliant patients, children less than 5 years old, and patients who fail oral antibiotic treatment after 48 hours.
- ▲ Daily follow-up in all cases until improvement is noted.

PROGNOSIS

Usually good when treated early. ▼

2.3 ORBITAL CELLULITIS



Infection and inflammation within the orbital cavity producing orbital signs and symptoms. May also involve the eyelids (Fig. 2.9).

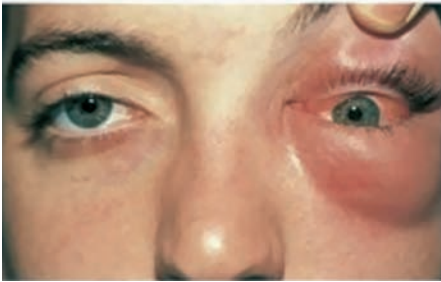

Fig. 2.9 Orbital Cellulitis

ETIOLOGY

Most commonly secondary to ethmoid sinusitis. May also result from frontal, maxillary, or sphenoid infection. Other causes include dacryocystitis, dental caries, intracranial infections, trauma and orbital surgery. Streptococcus and Staphylococcus species are most

common isolates. Haemophilus influenzae is common in children under 5. Fungal infections usually seen in patients with diabetes mellitus, malignancy or immunosuppression; and can be fatal due to the spread along the ophthalmic artery to the cranium.

SYMPTOMS:

- Decreased vision
- Pain
- Red eye
- Headache
- Diplopia
- "Bulging" eye
- Lid swelling
- Fever

SIGNS:

- Decreased visual acuity
- Fever
- Lid erythema, edema, and tenderness
- Limitation of or painful ocular movements
- Proptosis
- Positive relative afferent pupillary defect

- Conjunctival injection and chemosis
- Optic disc swelling may be present
- Cranial nerve (CN) V signs suggest orbital apex/ cavernous sinus involvement

DIFFERENTIAL DIAGNOSIS

Thyroid ophthalmopathy (adults), lacrimal gland tumors, trauma, carotid-cavernous fistula.

WORK-UP

- ▲ Complete ophthalmic history with attention to trauma, sinus disease, recent dental work or infections, history of diabetes or immunosuppression.
- ▲ Complete eye examination with attention to acuity, color vision, pupils, motility, exophthalmometry, lids, conjunctiva, sclera (including corneal sensitivity), CN V sensation and ophthalmoscopy.
- ▲ Check vital signs, head and neck lymph nodes, meningeal signs (nuchal rigidity) and sensorium.
- ▲ CT scan of orbits and paranasal sinuses.
- ▲ Lab tests: CBC with differential, blood cultures; wound culture if present.

MANAGEMENT

- ▲ Systemic intravenous antibiotics (1-week course):
Nafcillin 1-2g IV q.4h and Ceftriaxone 1-2g IV q.12-24h, or
Ampicillin-sulbactam 1,5-3,0g IV q.6h
- ▲ Topical antibiotics (Erythromycin ointment qid) for conjunctivitis or corneal exposure.
- ▲ Daily follow-up required to monitor visual acuity, color vision, ocular movements, proptosis, intraocular pressure, cornea and optic nerve.
- ▲ Systemic oral antibiotics (10-day course) after improvement on intravenous therapy:
Amoxicillin-clavulanate

Augmentin 250-500 mg po tid, or
Cefaclor 250-500 mg po tid, or Bactrim 1 double-strength tablet po bid in penicillin-allergic patients

- ▲ Subperiosteal abscess requires URGENT REFERRAL to orbital surgeon for systemic oral antibiotics (see above) and close observation, or surgical drainage.
- ▲ Otolaryngology consultation is indicated to obtain tissue diagnosis for opacified sinuses.
- ▲ Diabetic or immunocompromised patients are at high risk for fungi. Given the very high mortality rate, emergent debridement and biopsy, systemic intravenous antifungal medications (Amphotericin B 0,25-1,0 mg/kg IV divided equally q.6h), and management of underlying medical disorders are indicated

PROGNOSIS

Depends on organism and extent of inflammation. May develop cavernous sinus thrombosis or meningitis which produces permanent neurologic defects.

POINTS TO REMEMBER

- ▲ Preseptal cellulitis may progress to orbital cellulitis, which is potentially life-threatening or vision-threatening.
- ▲ Orbital cellulitis may cause cavernous sinus thrombosis or intracranial abscess without appropriate treatment.
- ▲ Must follow patients closely to prevent the development of deeper infection.
 - decreased vision
 - decreased ocular motility
 - afferent pupillary defect
 - proptosis and chemosis ▼

DIFFERENTIAL DIAGNOSIS

PRESEPTAL/ORBITAL CELLULITIS

	Preseptal cellulites	Orbital cellulitis
Visual acuity	Normal	Decreased
Color vision	Normal	Abnormal
Eyelid	swelling and erythema	swelling and erythema
Extraocular movement	full, painless	restricted painful
Pupillary response	Normal	Abnormal
Positive APD	no	yes
Optic Disc swelling	no	possible



3. CONJUNCTIVA/ CORNEA DISEASES

3.1 ALLERGIC CONJUNCTIVITIS (Fig 3.1)

ETIOLOGY

Type 1 hypersensitivity reaction to airborne allergens.

SYMPTOMS

- Itching
- Watery discharge
- History of allergies

SIGNS

- Chemosis
- Red and edematous eyelids
- Conjunctival papillae
- Preauricular node is not palpable

TREATMENT

1. Eliminate the inciting agent.
2. Cool compress several times per day.
3. Topical drops, depending on severity
 - **Mild:** Artificial tears four to eight times per day. The reason is that the mucus cells are affected and do not produce the mucin to allow the "spreadability" of the tears.
 - **Moderate:** Vasoconstrictor/ antihistamine only 2 to 3 X per day as patients often become addicted on this treatment and take it hourly.

**Beware that it can cause an attack of angle closure.
Be aware of rebound vasodilation after prolonged use.**

Olopatadine 0.1%, Iodoxamide 0.1%, nedocromil 2%, or ketotifen 0.025% b.i.d. may help relieve itching; etorolac 0.5% q.i.d. may occasionally reduce symptoms.

4. Non-steroidal anti-inflammatory drugs (Diclofenac 0.1%, etc.)
5. Oral antihistamines in moderate to severe cases can be very helpful.

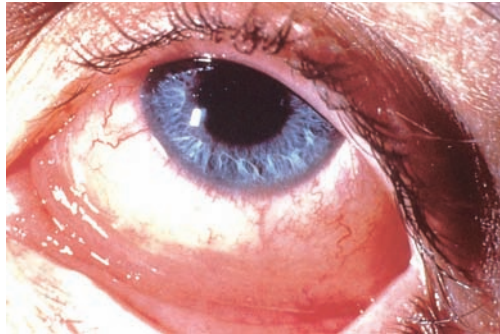


Fig. 3.1 Allergic Conjunctivitis

POINTS TO REMEMBER

Routine use of topical antibiotics or steroids for allergic conjunctivitis is discouraged.

FOLLOW-UP

In 2 weeks. If topical steroids are being used, patients should be monitored for steroid side effects. The steroids should be slowly tapered. ▼

3. 2 VIRAL CONJUNCTIVITIS (Fig. 3.2)

ETIOLOGY

Common causes

- Adenovirus may occur as the highly contagious (epidemic keratoconjunctivitis [EKC])
- Herpes simplex virus
- Enterovirus

Rarely causes

- Measles

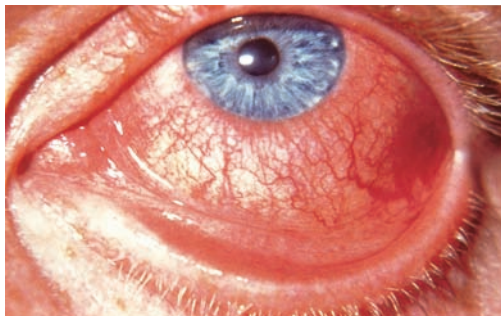


Fig. 3.2 Viral conjunctivitis

- Influenza
- Mumps

SYMPTOMS

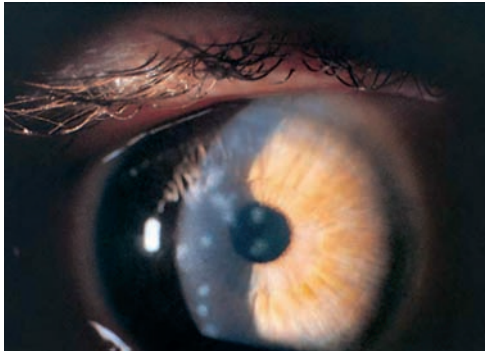- Itching
- Burning
- Foreign body sensation

History of recent upper respiratory tract infection or contact with someone who was sick

It usually starts in one eye and involves the other eye a few days later.

SIGNS

- Inferior palpebral conjunctival follicles
- Palpebral preauricular lymph node, commonly found with EKC
- Watery, mucous discharge
- Red and edematous eyelids
- Pinpoint subconjunctival hemorrhages
- Membrane/ pseudomembrane
- Subepithelial infiltrates (SEIs) may develop 1 to 2 weeks after the onset of the conjunctivitis usually within the central cornea with EKC (Fig. 3.3)



Subepithelial infiltrates

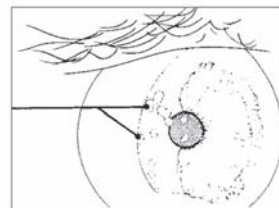


Fig. 3.3 Adenovirus. Subepithelial infiltrates

WORKUP

No conjunctival culture or swabbing are indicated unless the discharge is excessive or the condition becomes chronic

Fluorescein staining to rule out the branched shaped corneal epithelial lesion of herpetic keratitis.

TREATMENT

1. Artificial tears four to eight times per day for 1 to 3 weeks.
2. Cool compresses several times per day for 1 to 2 weeks
3. Vasoconstrictor/antihistamine (e.g., naphasoline/ pheniramine Noseline) q.i.d., if itching is severe.
4. If a membrane/ pseudomembrane is present, it should be gently peeled.
5. If a membrane/ pseudomembrane is present or if SEIs reduce vision, use NSAIDs (Diclofenac 0.1%).
6. Counsel the patient that viral conjunctivitis is a self-limiting condition that typically gets worse for the first 4 to 7 days after onset and may not resolve for 2 to 3 weeks
7. Viral conjunctivitis is **VERY CONTAGIOUS, USUALLY FOR 10 to 12 days** from the day of onset.
Patients should avoid touching their eyes, shaking hands with other people, sharing towels, and so forth.
Restrict work and school for patients with significant exposure to others as long as the eyes are red and weeping.
8. Recommend frequent handwashing.

POINTS TO REMEMBER

Routine use of topical antibiotics or steroids for viral conjunctivitis is discouraged.

FOLLOW-UP

In 1 to 2 weeks, but sooner if the condition worsens significantly.

VARIANTS (TREATED THE SAME AS THE PRECEDING DIRECTIONS) PHARYNGOCONJUNCTIVAL FEVER

As earlier, but associated with pharyngitis and fever: **USUALLY IN CHILDREN**

ACUTE HEMORRHAGIC CONJUNCTIVITIS

As earlier, but associated with a large subconjunctival hemorrhage. Associated with enterovirus and lasts 1 to 2 weeks. Tends to occur in tropical regions.

POINTS TO REMEMBER

MANY SYSTEMIC VIRAL SYNDROMES (e.g., measles, mumps, influenza), as mentioned earlier, CAN CAUSE A NONSPECIFIC CONJUNCTIVITIS.

THE UNDERLYING CONDITION SHOULD BE MANAGED APPROPRIATELY; the eyes are treated with artificial tears four to eight times per day.

3.3 VERNAL KERATOCONJUNCTIVITIS (VC)

VC is an allergic conjunctivitis characterized by seasonal exacerbations most commonly seen in young boys.

ETIOLOGY

Immune mediated, pollen- or mold-specific immunoglobulins E and G (IgE and IgG)

SIGNS AND SYMPTOMS

Itching, redness, watery discharge

OPHTHALMIC FINDINGS

- Edema of lids and conj.
- Boggy conjunctival edema.
- Papillary conjunctivitis may form giant papillae (Fig. 3.4).
- Limbal vernal disease is characterized by nodular limbal swelling with white centers (Trantas spots) (Fig. 3.5)
- Corneal vernal plaques may lead to subepithelial scarring

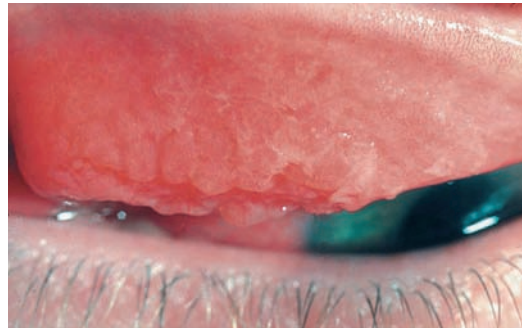DEMOGRAPHICS

- ▲ More common in boys
- ▲ History of asthma, atopy, or eczema

TREATMENT · Steroids

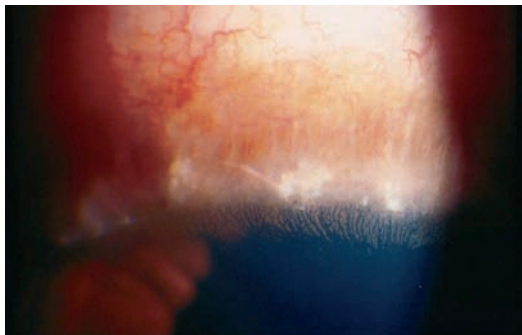- ▲ Mast cell stabilizers
- ▲ Topical antihistamine, decongestant.
- ▲ Artificial tears
- ▲ Systemic allergy treatment

Fig.3.4 Giant papillae of the upper palpebral conjunctiva in vernal oconjunctivitis



© 2005 Elsevier Ltd. Spalton et al: Atlas of Clinical Ophthalmology 3e

Fig.3.5 Trantas dots in vernal keratoconjunctivitis



© 2005 Elsevier Ltd. Spalton et al: Atlas of Clinical Ophthalmology 3e

3.4 DRY EYE SYNDROME

SYMPTOMS:

- Burning or foreign body sensations
- May have excess tearing, often exacerbated by smoke, wind, heat, low humidity or prolonged use of the eye.

Usually bilateral and chronic (although patients sometimes present with recent onset in one eye). Often causes more discomfort than the clinical signs would suggest.

CRITICAL SIGNS:

(Either or both may be present)

- ▲ Scanty tear meniscus seen at the inferior eyelid margin. The meniscus should be at least 1mm in height and have a convex shape.
- ▲ Decreased tear break-up time (Fig. 3.6). The time measured from a blink to the appearance of a tear film defect (using fluorescein stain) should be longer than 10 seconds.

OTHER SIGNS:

- ▲ Punctate corneal and/or conjunctival fluorescein or rose bengal staining, usually inferiorly or in the interpalpebral area (Fig 3.7).
- ▲ Excess mucus or debris in the tear film and filaments on the cornea may be found (Fig 3.8).

DIFFERENTIAL DIAGNOSIS

- ▲ Blepharitis (eyelid margin crusting, thickening, erythema and teleangiectasias often seen in combination with dry eyes).
- ▲ Eyelid abnormality leading to exposure (exposure keratopathy), often secondary to a seventh-nerve palsy, trauma, a chemical or thermal burn, a congenital anomaly, senile ectropion or other causes.
- ▲ Nocturnal lagophthalmos (eyelids remain partially open while asleep).

ETIOLOGY

- ▲ Idiopathic
- ▲ Collagen-vascular disease (e.g. Sjgren's syndrome, rheumatoid arthritis, Wegener's granulomatosis, systemic lupus erythematosus).
- ▲ Conjunctival scarring (e.g. ocular pemphigoid, Stevens-Johnson syndrome, trachoma, chemical burn).
- ▲ Drugs (e.g. oral contraceptives, antihypertensives that reduce the water content of body, antihistamines, beta-blockers, phenothiazines, atropine).
- ▲ Infiltration of the lacrimal glands (e.g. sarcoidosis, tumor).
- ▲ Postradiation fibrosis of the lacrimal glands.
- ▲ Vitamin A deficiency.

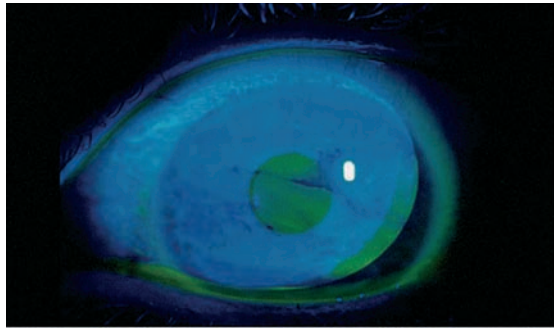


Fig.3.6
Tear film breakup time

© 2005 Elsevier Ltd. Spalton et al: Atlas of Clinical Ophthalmology 3e

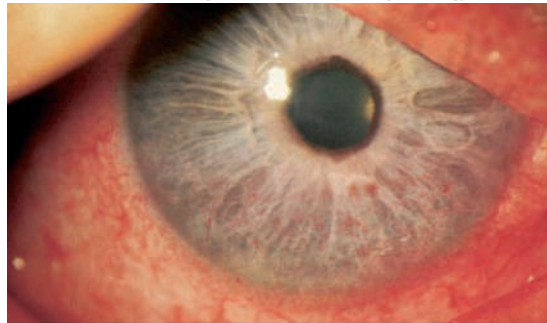


Fig.3.7
Keratoconjunctivitis sicca

© 2005 Elsevier Ltd. Spalton et al: Atlas of Clinical Ophthalmology 3e

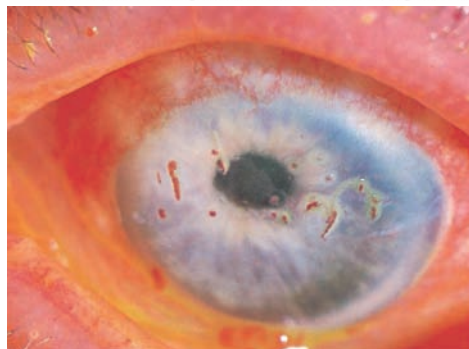


Fig.3.8
Mucous in tear film

© 2005 Elsevier Ltd. Spalton et al: Atlas of Clinical Ophthalmology 3e

WORK-UP

1. History and external examination to detect underlying etiology
2. Slit-lamp examination: using fluorescein stain and/or rose bengal staining, examine the tear meniscus and tear break-up time.

3. Schirmer's test

Technique: Schirmer filter paper is placed at the junction of the middle and lateral one third of the lower eyelid in each eye for 5 minutes, after drying the eye of excess tears.

Anesthetized topical anesthetic (Tetracaine 0,5%) is applied before drying with a cotton swab and placing the filter paper. This method measures basal tearing only.

Normal = wetting of 10 mm in 5 minutes.

TREATMENT

Mild

Artificial tears qid

Moderate

1. Increase frequency of artificial tear application up to every 1-2 hours use preservative-free artificial tears.
2. Can add a lubricating ointment at bedtime (e.g. Hypo tears ointment, Refresh PM).

Severe

1. Lubricating ointment (e.g. Refresh PM) 2-3 times per day during the day-time with preservative-free artificial tears q.1-2h.
2. Patch the lubrication at night (may need to patch during the day).
3. If mucus strands or filaments are present, remove with forceps and consider 10% acetylcysteine (e.g. Mucomyst) qid.
4. If the above measures are unsuccessful, consider punctal occlusion with collagen or silicone plugs or by electric cautery (after a trial of the former).

5. Consider lateral tarsorrhaphy if all of the previous measures fail. A temporary adhesive-tape tarsorrhaphy (to tape the lateral one third of the eyelid closed) can also be used before a surgical tarsorrhaphy.

POINTS TO REMEMBER

1. In addition to treating the dry eye, treatment for contributing disorders (e.g. blepharitis, exposure keratopathy) should be instituted if these conditions are present.
2. Always use preservative-free artificial tears if using them more frequently than every 3 hours to prevent preservative toxicity.
3. If the history suggests presence of a previously undiagnosed collagen-vascular disease (e.g. history of arthritic pain), referral should be made to an internist or rheumatologist for further evaluation.

FOLLOW-UP

In days to weeks, depending upon the severity of the drying changes and the symptoms. Anyone with severe dry eyes caused by an underlying chronic systemic disease (e.g. rheumatoid arthritis, sarcoidosis, ocular pemphigoid) may need to be monitored more closely.

POINTS TO REMEMBER

Patients with severe dry eyes should be discouraged from wearing contact lenses. Patients with Sjögren's syndrome have an increased incidence of lymphoma and mucous-membrane problems and may require internal medicine, rheumatological, dental, and gynecological follow-up.▼

3. 5 CORNEAL ABRASION

Corneal epithelial defect usually due to trauma (Fig 3.9).

SIGNS AND SYMPTOMS:

- Pain
- Foreign body sensation
- Photophobia
- Tearing
- Red eye
- May have normal or decreased visual acuity
- Conjunctival injection
- Epithelial defect that stains with fluorescein

MANAGEMENT

- ▲ Topical antibiotic drop: Tobramycin (Tobrex) qid or ointment (Tetracycline 1%) qid.
- ▲ Consider topical non-steroidal anti-inflammatory drugs (NSAID) – Diclofenac sodium 0,1% tid for 48-72h for pain.
- ▲ Consider topical cycloplegic agent (Cyclopentolate 1% bid) for pain and photophobia, obligatory if central cornea is involved.▼

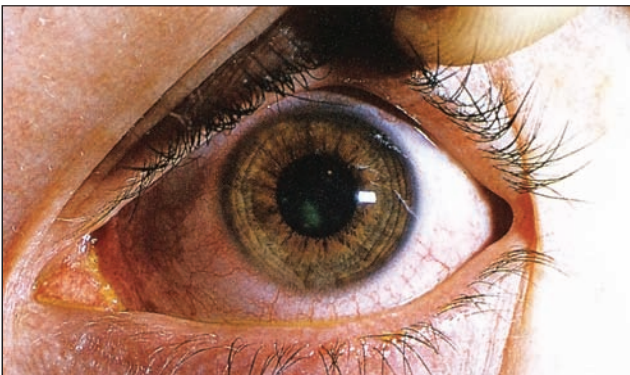

Fig.3.9
Corneal abrasion stained
by fluorescein

3. 6 BACTERIAL CORNEAL KERATITIS (CORNEAL ULCER)

Destruction of corneal tissue (epithelium and stroma) due to inflammation from an infectious organism (Fig 3.10).

Risks include contact lens wear, trauma, dry eyes, exposure keratopathy, bullous keratopathy, neurotrophic cornea and lid abnormalitis.

ETIOLOGY

Bacterial

Most common infectious source: usually due to Staph. aureus, Staph. epidermidis, Streptococcus pneumoniae, Pseudomonas aeruginosa Haemophilus influenzae, Moraxella catarrhalis; beware of Neisseria species and Haemophilus because they can penetrate an intact epithelium.

SYMPTOMS:

- Pain
- Discharge
- Photophobia
- Red eye
- Decreased vision
- May notice white spots on the cornea.

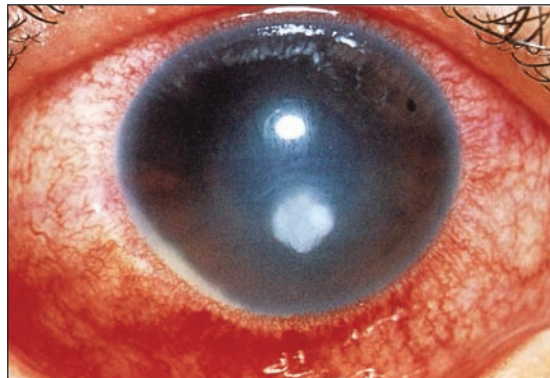


Fig.3.10
Microbial Keratitis

SIGNS:

Normal or decreased visual acuity, mucopurulent discharge, conjunctival injection, ciliary injection, white corneal infiltrate with overlying epithelial defect, corneal edema, Descemet's folds (If more severe, anterior chamber cells and flare, hypopyon, corneal thinning, descemetocele, increased intraocular pressure).

WORK-UP

- ▲ Complete ophthalmic history with attention to contact lens use and care regimen.
- ▲ Complete eye examination with attention to cornea (sensation, size and depth of ulcer, character of infiltrate, fluorescein staining, amount of thinning) and anterior chamber.
- ▲ Lab tests: scrape corneal ulcer with sterile spatula or blade and smear on microbiology slides.

MANAGEMENT

- ▲ Suspend contact lens use and throw out soft contact lens used in that eye.
- ▲ Consider a bandage contact lens to seal the perforations, and penetrating keratoplasty
- ▲ **NEVER PATCH CORNEAL ULCER**
- ▲ Ulcers require daily follow-up initially, and severe ones require hospital admission.
- ▲ **If the organism is in doubt, treat as a bacterial ulcer until the culture results return.**

TREATMENT

- ▲ **Small infiltrates** (< 2 mm): broad spectrum topical antibiotic Moxifloxacin (Moxicin) q.1h initially, then taper slowly).
- ▲ **Larger ulcers:** broad spectrum fortified topical antibiotics (Tobramycin

13.6 mg/ml)* - see below and Cefazolin 50 mg/ml alternating q.1h (which means taking a drop every 30 minutes) for 24-72 hours, then taper slowly); consider subconjunctival antibiotic injections in noncompliant patients

- ▲ Tailor antibiotic choices as culture and Gram stain results return.
- ▲ Topical cycloplegic agent (Scopolamine 0,25% or Atropine 1% bid to qid).
- ▲ TOPICAL STEROIDS (Prednisolone acetate 1% dosed at lower frequency than topical antibiotics) SHOULD BE AVOIDED UNTIL IMPROVEMENT IS NOTED (USUALLY AFTER 48-72 HOURS).
- ▲ Systemic antibiotics for corneal perforation or scleral involvement or endophthalmitis.

PROGNOSIS

Depends on organism, size, location and response to treatment; sequelae may range from a small corneal scar without alteration of vision to corneal perforation requiring emergent grafting.

* Fortified Tobramycin

With a syringe, inject 2 ml of tobramycin, 40 mg/ml directly into a 5-ml bottle of tobramycin, 0.3%, ophthalmic solution (Tobrex). Refrigerate. Expires after 14 days. ▼

3. 7 HERPETIC KERATITIS

Herpes Simplex Virus (HSV) may cause primary systemic infection with ocular involvement or recurrent ocular involvement due to latent infection. HSV infection may manifest a variety of corneal findings.

Primary Disease: viral prodrome with fever, upper respiratory infection, and possible follicular conjunctivitis, preauricular node and

cutaneous vesicles on eyelids, rarely with corneal epithelial punctate lesions or dendrites.

Recurrent or Secondary Disease: usually in adulthood. 90% of adult population has Herpes Simplex antibodies but the attack was subclinical.

1. Fever blister of lip.
2. Corneal dendritic figure most common ocular presentation (Fig 3.11, 3.12).
3. Trigger mechanism: febrile illness, menses, sunburn, "stress".
4. Decreased corneal sensation, usually unilateral and the most common cause of corneal ulcers after those caused by soft contact lenses. 25% recurrence rate within 2 years after the first attack of dendritic keratitis and 45% within 2 years after the second attack.

PRESENTATION

Epithelial Infectious Keratitis: dendritic (Fig 3.11) or geographic (Fig 3.13) ulcers.

SIGNS AND SYMPTOMS:

- Pain
- Photophobia
- Tearing
- Redness
- Blurry vision

Dendrites are true ulcers that are thin and branching with terminal bulbs and swollen borders.

Fluorescein staining are like dendrites.

Geographic ulcers are similar to dendrites but are larger, widened lesions.

Immune Stromal (or Interstitial)
"Disciform" Keratitis (Fig. 3.14)

SIGNS AND SYMPTOMS:

Blurry vision due to:

- hazy stromal infiltrate: a disc-like or round local area of edema and thickening of stroma
- keratitic precipitates (KP) due to hypersensitivity stromal reaction
- scarring
- Epithelium is usually intact.

Necrotizing Stromal Keratitis (Fig. 3.15): direct viral stromal infection causing necrosis, an epithelial defect and a dense infiltrate

Endothelitis: focal or "disciform" stromal edema with underlying endothelial KP and anterior chamber cells.

DIFFERENTIAL DIAGNOSIS

- ▲ Epithelial disease: HZV, pseudodendrites secondary to contact lens wear, or Acanthamoeba infection.
- ▲ Neurotrophic ulcer
- ▲ Stromal disease: acute bacterial or other corneal ulcers.

MANAGEMENT

MEDICAL TREATMENT

Diagnosis is usually clinical.

- ▲ Epithelial disease: Acyclovir 3% eye ointment (Zovirax) 5 times daily.
May substitute oral antiviral (Acyclovir 400 mg 5 times a day or Valcyclovir (Valtrex) 500 mg qd).
Cycloplegic agent

POINTS TO REMEMBER

Topical steroids are contraindicated due to danger of corneal perforation.

▲ Immune stromal disease:

Attempt to withhold steroids until the resolution of the active epithelial disease, judged on the basis of absence of fluorescein stain.

For a moderate to severe inflammation with associated symptoms and decreased visual acuity, diluted steroids every two hours with follow-up are indicated.

Topical steroid dosage is tailored to the patient and tapered slowly with a close follow-up until a minimum "flare" dosage is achieved.

Oral steroids are indicated for severe cases.

A suppression dosage of oral antiviral (Acyclovir 400 mg bid) avoids corneal toxicity and is useful for long-term prophylaxis.

SURGERY

1. Penetrating keratoplasty ideally 6 months after the resolution of active stromal keratitis, control of uveitis and glaucoma. Recurrence rate in transplants is approximately 20%.
2. Conjunctival flap is frequently needed for large indolent ulcers and corneal perforations. ▼

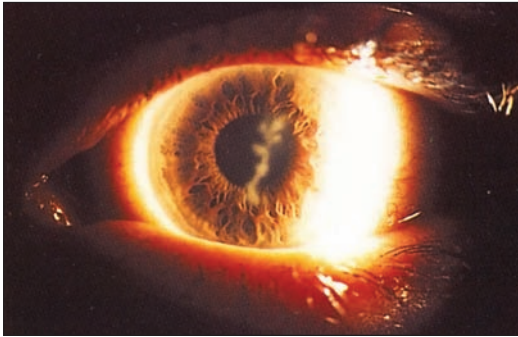

Fig.3.11 Dendritic lesion of the corneal epithelium due to Herpes Simplex keratitis

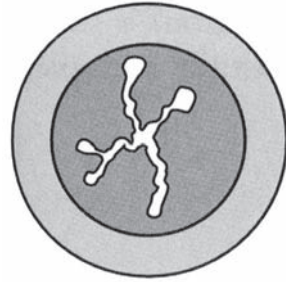

Fig.3.12 Schematic of dendritic lesion of the corneal epithelium due to Herpes Simplex keratitis

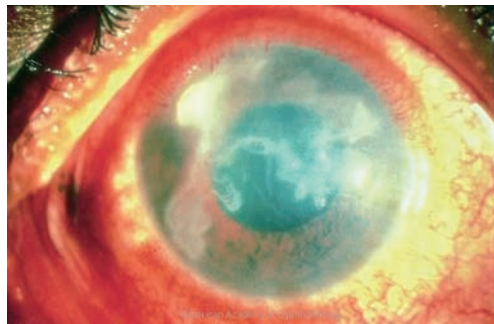


Fig.3.13
Herpetic geographic epithelial keratitis

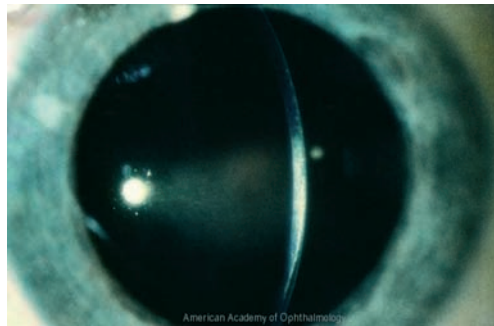


Fig 3.14
Herpetic interstitial keratitis

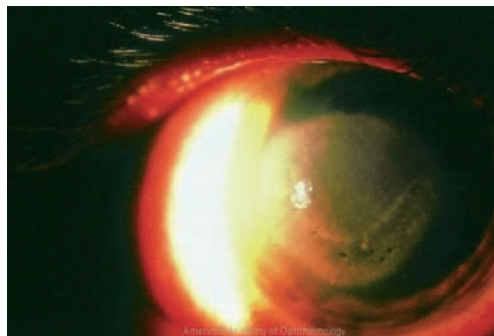


Fig 3.15
Necrotizing herpetic stromal keratitis

3.8 HERPES ZOSTER OPHTHALMICUS

Herpes Zoster virus (HZV) is acquired primarily during childhood as chickenpox (varicella). The virus remains latent in sensory ganglia; it may become activated spontaneously or during immunosuppression.

SIGNS

- Skin eruptions in the distribution of sensory nerves.
- Trigeminal nerves are the second most frequently involved after the thoracic nerves; ophthalmic division is most commonly involved.
- Skin eruption at the tip of the nose (Fig. 3.16); indicates nasociliary nerve involvement (higher incidence of ocular involvement, including uveitis).

EYE:

- **Lid:**
vesicular or ulcerative skin eruptions (may have bacterial superinfection); lash loss.
- **Canaliculitis.**
Myositis; episcleritis, scleritis.
Conjunctivitis: papillary or follicular.

Cornea:

1. Decreased corneal sensation.
2. HZV dendritis: no terminal bulbs and consists of heaped-up epithelium (Fig. 3.17).
3. Stroma: nummular, interstitial, disciform keratitis.
4. Trophic and recurrent epithelial defects.
5. Corneal stromal melt (Fig. 3.18).
Iridocyclitis or keratouveitis (Fig. 3.19).

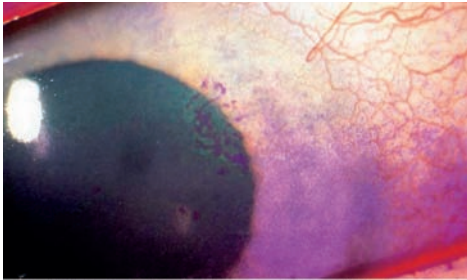
Elevated IOP due to trabeculitis or iridocyclitis.

Other: vitritis, retinal vasculitis, retinal necrosis, choroiditis, occlusion of the central retinal or ophthalmic arteries, and optic neuritis.

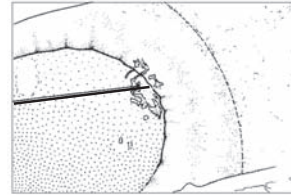
Fig 3.16
Herpes zoster ophthalmicus

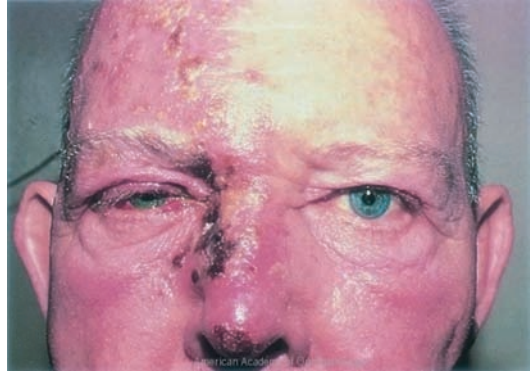

Fig 3.17 Herpes zoster

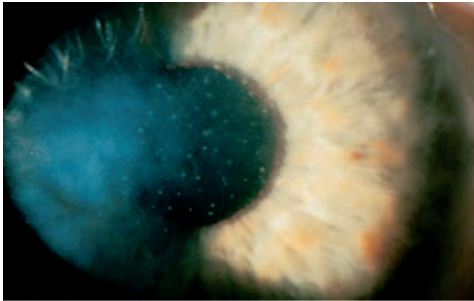


HZV dendritis

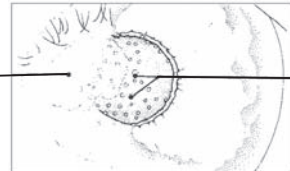


© 2005 Elsevier Ltd. Spalton et al: Atlas of Clinical Ophthalmology 3e

Fig 3.18 Disciform keratitis



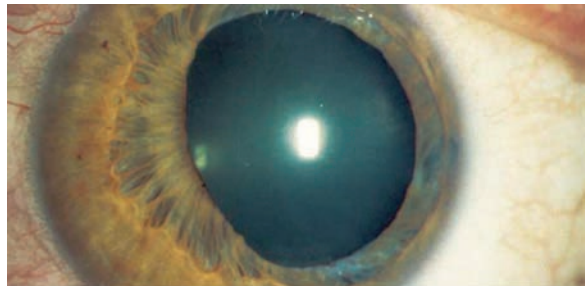
stromal edema



KP

© 2005 Elsevier Ltd. Spalton et al: Atlas of Clinical Ophthalmology 3e

Fig 3.19
Iris atrophy after
Herpes zoster uveitis



© 2005 Elsevier Ltd. Spalton et al: Atlas of Clinical Ophthalmology 3e

TREATMENT

1. Oral antiviral within 5 days of onset: Acyclovir 800 mg 5x/ day, Valacyclovir 1000mg tid) x 7 days.
2. Oral steroid: prednisone 60 mg qd x 1 week, then 30mg x 1 week, then 15 mg qd x 1 week.
3. Cycloplegic agents and analgetics as needed.
4. Topical steroids for nummular, disciform, and interstitial keratitis, iridocyclitis, and glaucoma secondary to uveitis.
5. Persistent epithelial defects: treated with pressure patching, bandage contact lens with frequent lubrication; tarsorrhaphy, conjunctival flap, or corneal transplantation may be needed in severe cases. ▼



4. SCLERA/ UVEA DISEASES

4.1 ANTERIOR UVEITIS (IRITIS /IRIDOCYCLITIS)

ETIOLOGY

ACUTE

- Idiopathic
- HLA-B27 -associated uveitis (especially young men with low back pain, seronegative spondiloarthritis) (Fig. 4.1).
- Lens-induced uveitis (Fig. 4.2) Phacoanaphylactic uveitis or phacolytic glaucoma.
- Postoperative iritis.
- Behcet disease (Fig. 4.15).
- Rare causes: mumps, influenza , adenovirus, measles, chlamydia

CHRONIC

- Juvenile rheumatoid arthritis (JRA) (Fig. 4.3)
- Fuchs heterochromic iridocyclitis (FHIC) Should be (FHIC)
- CHRONIC, Usually with Granulomatous Signs (Mutton-Fat Keratic precipitates, iris Nodules) (Fig. 4.4, 4.5)
- Sarcoidosis (Fig. 4.6, 4.7, 4.8)
- Herpes simplex/herpes zoster/ varicella
- Syphilis
- Tuberculosis (Fig. 4.9)
- Brucellosis

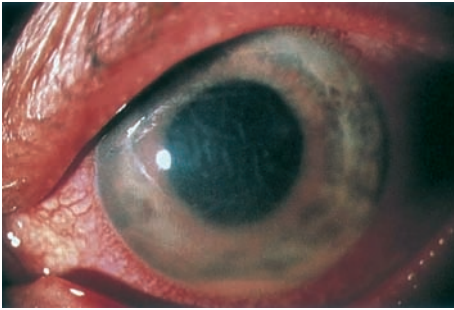


Fig. 4.1 Acute HLA-B27 positive anterior uveitis with pain, photophobia, marked injection fixed pupils, loss of iris detail from corneal edema and hypopyon

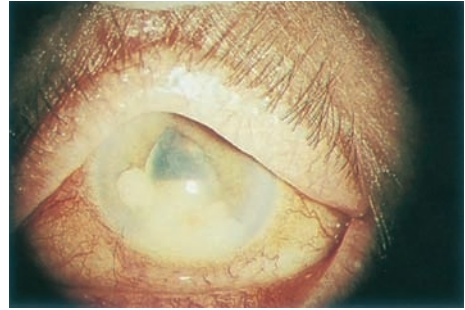


Fig. 4.2 Phacoantigenetic reaction following phacoemulsification

Fig. 4.3 Juvenile rheumatoid arthritis, chronic iridocyclitis, cataract

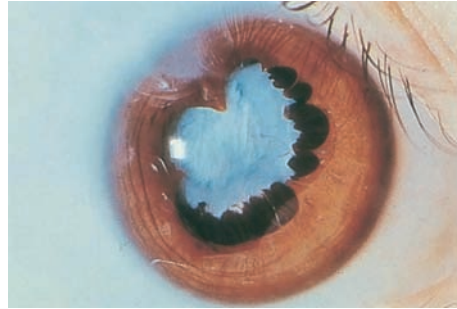
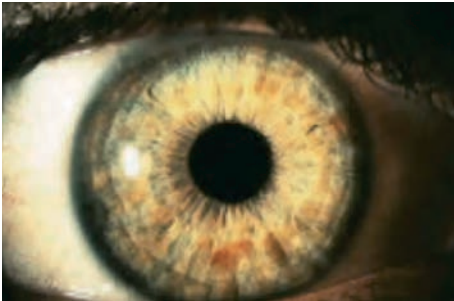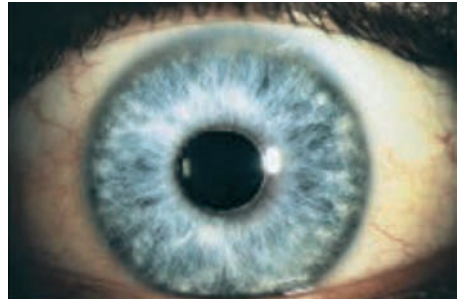


Fig. 4.4 Heterochromia in Fuchs heterochromic iridocyclitis



A Right eye



B Left eye

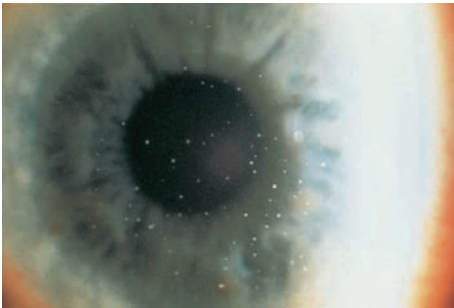

Fig. 4.5 Diffusely distributed keratic precipitates in Fuchs heterochromic iridocyclitis.

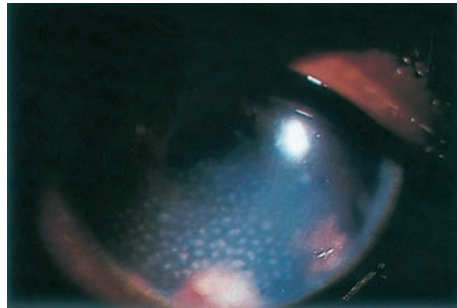


Fig. 4.6 Sarcoidosis, keratic precipitates and iridocyclitis

SYMPTOMS

ACUTE

- Pain
- Red eye
- Photophobia

CHRONIC

- Decreased vision
- Possibly have periods of exacerbations and remissions, with few or none of acute symptoms (especially JRA)

SIGNS

- Cells (Fig. 4.10) and flare (Fig. 4.1) in the anterior chamber
- Ciliary flush
- Keratic precipitates (KP):
 Fine ("stellate"; typically covers entire corneal endothelium): herpetic, FHIC, Sarcoidosis, Toxoplasmosis, others (Fig. 4.12).
 Large, greasy ("mutton-fat"; mostly on inferior cornea): sarcoidosis, syphilis, tuberculosis, lens-induced, Vogt-Koyanagi-Harada (VKH) syndrome,
- Sympathetic ophthalmia, herpetic, others (Fig. 4.13)
- Low intraocular pressure (IOP; more commonly seen)
- Elevated IOP (especially herpetic, lens induced,
- FHIC, Sarcoidosis, Toxoplasmosis, Posner-Schlossman syndrome)
- Fibrin (HLA-B27 or infectious endophthalmitis) (Fig. 4.14)
- Hypopion (HLA-B27, Behcet disease, tumor) (Fig. 4.15)
- Iris nodules (sarcoidosis, syphilis ,tuberculosis) (Fig. 4.17)
- Iris atrophy (herpetic, FHIC) (Fig. 3.19)
- Iris heterochromia (FHIC) (Fig. 4.4)
- Iris synechiae (especially HLA-B27,sarcoidosis) (Fig. 4.16)
- Band keratopathy (especially JRA in younger patients, any chronic uveitis in older)
- Uveitis in a "quiet eye" (consider JRA, FHIC, masquerade syndromes); cystoid macular edema (CME), can occur with any type of uveitis.

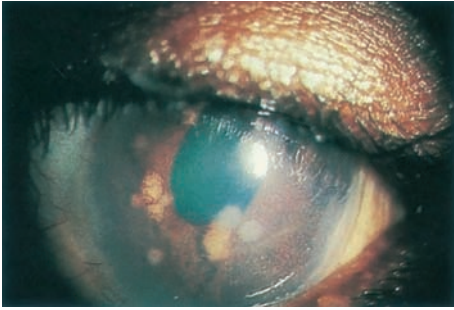


Fig. 4.7 Sarcoidosis, iris nodules

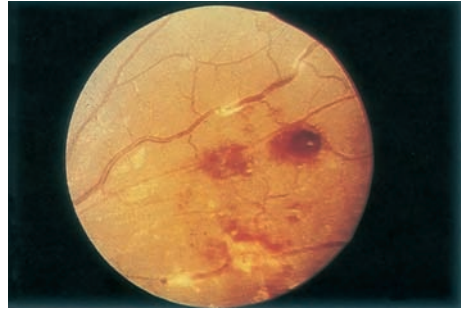


Fig. 4.8 Sarcoidosis, retinal vascular sheathing

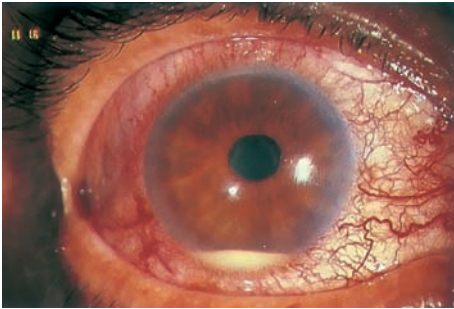


Fig. 4.9 Acute tuberculous uveitis with hypopyon posterior synechiae, vitritis, retinal vasculitis, and ceptoid macular edema

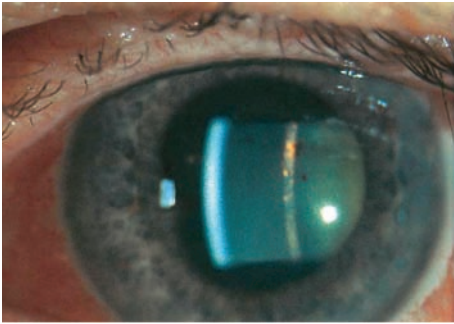


Fig. 4.10 Flare in the anterior chamber

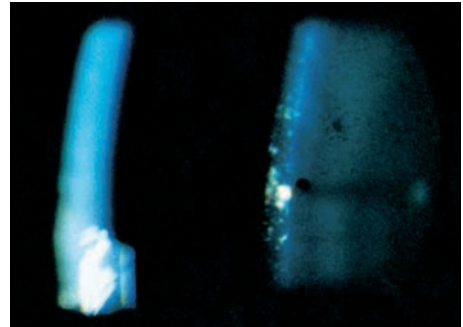


Fig. 4.11 Cells in the anterior chamber

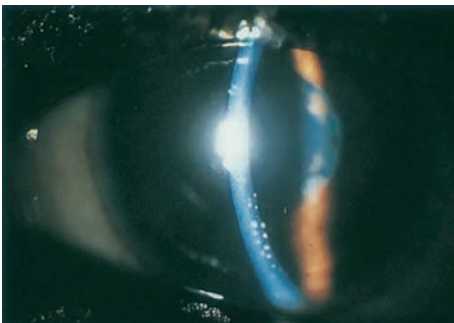


Fig. 4.12 Keratic precipitates (medium and small) with broken posterior synechiae

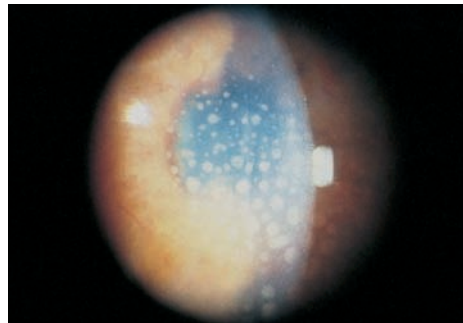


Fig. 4.13 Large "mutton fat" keratic precipitates in a patient with sarcoidosis

DIFFERENTIAL DIAGNOSIS

- Posterior uveitis with spillover into the anterior chamber
- Traumatic iritis
- Drug-induced uveitis (cidofovir, rifabutin, pamidronate, sulfonamides)
- Infectious keratouveitis
- Infectious endophthalmitis
- Tumor

WORKUP

OBTAIN A HISTORY AND REVIEW OF SYSTEMS

POINTS TO REMEMBER

Autoimmune diseases are uncommon in the very young or very old- consider masquerades.

Inflammatory arthritis typically presents with stiffness in the morning that improves after activity.

1. Complete ocular examination, including an IOP check and a dilated fundus examination. The vitreous should be evaluated for cells.
2. A laboratory workup may be unnecessary in certain situations:
 - First-time occurrence of a mild, unilateral, non-granulomatous uveitis with a history and examination that are not suggestive of a systemic disease.
 - Uveitis occurring in the setting of a known systemic disease such as sarcoidosis or the patient is taking medicines known to cause uveitis (e.g., rifabutin).
 - Clinical findings are classic for a particular diagnosis (e.g., herpetic keratouveitis, FHC, toxoplasmosis).
3. If the uveitis is bilateral, granulomatous, or recurrent, and the history and examination are unremarkable, then a nonspecific initial workup is required

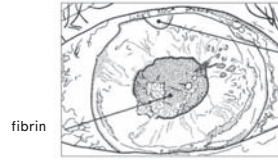
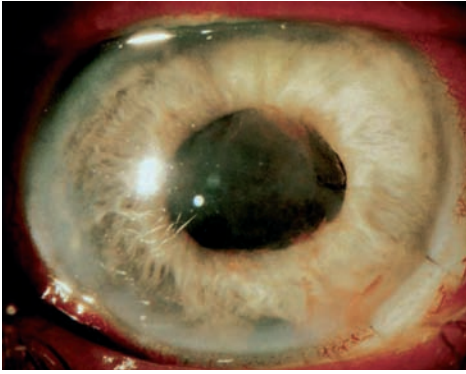


Fig.4.14 Fibrin in the anterior chamber

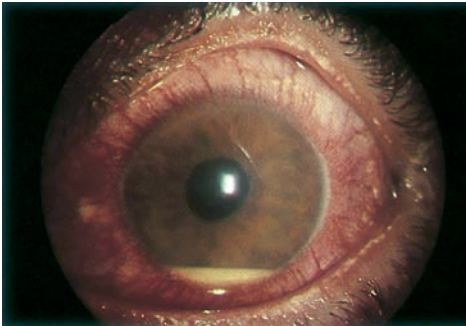


Fig.4.15 Behcet syndrome, hypopyon

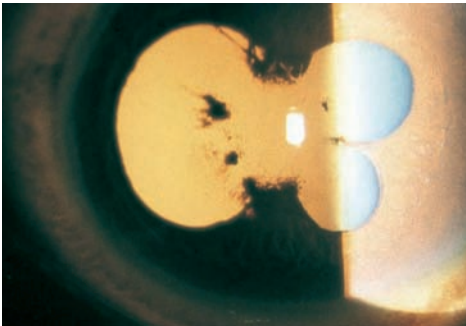


Fig.4.16 Multiple posterior synechiae preventing complete dilation of the pupil

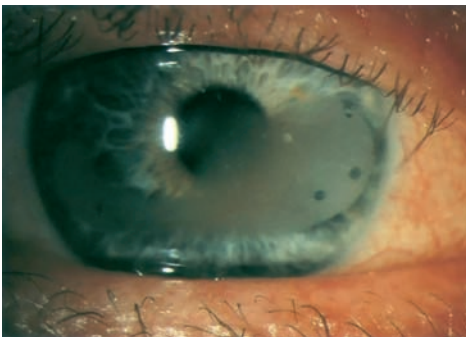


Fig. 4.17 Chronic calcific band keratopathy

TREATMENT

1. Cycloplegic (homatropine 5% q.i.d., for mild to moderate inflammation; atropine, 1% b.id. to q.i.d., for severe inflammation. Use atropine with caution in patients at risk for urinary retention).
2. Topical steroid (prednisolone acetate, 1%, one drop q1-6h, depending on the severity). Most cases of moderate to severe acute uveitis require q1-2h dosing initially.

If the anterior uveitis is severe and is not responding well to frequent topical steroids, then consider periocular repository steroids (e.g., triamcinolone 20 to 40 mg subtenon injection). Before injecting depot steroids periocularly, it is wise to use topical steroids at full strength for several weeks to make certain that the patient does not experience a significant IOP increase from steroids.

3. If there is no improvement on maximal topical and repository steroids, or if the uveitis is bilateral and severe, consider systemic steroids, or referral to arheumatologist for immunosuppressive therapy. Consider referral to a uveitis specialist.
4. Treat secondary glaucoma with aqueous suppressants.

POINTS TO REMEMBER

Pilocarpine or prostaglandines are contraindicated in uveitis.

5. If an exact etiology for the anterior uveitis is determined, then the specific management should be added to these treatments.

FOLLOW-UP

1. Every 1 to 7 days in the acute phase, depending on the severity; every 1 to 6 months when stable.
2. At each visit, the anterior chamber reaction and IOP should be evaluated.

3. A vitreous and fundus examination should be performed for all flare-ups, when vision is affected, or every 3 to 6 months.
4. If the anterior chamber reaction is improving, then the steroid drops can be slowly tapered [usually one drop per day every 3 to 7 days (e.g., q.i.d. for 1 week, then t.i.d. for 1 week, then b.i.d. for 1 week)]

Steroids are usually discontinued once all cells have disappeared from the anterior chamber (flare is often still present). Rarely, long-term low-dose steroids every day or every other day are required to keep the inflammation from recurring. Punctal occlusion techniques may increase potency of the drug and decrease systemic absorption.

The cycloplegic agents also can be tapered as the anterior chamber reaction improves. Cycloplegics should be used at least every evening until the anterior chamber is free of cells.

POINTS TO REMEMBER

As with most ocular and systemic diseases requiring steroid therapy, the steroid (be it topical or systemic) should never be discontinued abruptly.

SUDDEN DISCONTINUATION OF STEROIDS CAN LEAD TO SEVERE REBOUND INFLAMMATION
IT IS IMPORTANT TO REVEAL EARLY IOP SPIKES IN STEROID-RESPONDING PATIENTS AND CLOSELY FOLLOW THEM UP. ▼

4. 2 POSTERIOS UVEITIS

4.2.1 OCULAR TOXOPLASMOSIS

Ocular toxoplasmosis is caused by *Toxoplasma gondii* infection resulting in vitritis and retinitis USUALLY adjacent to previous chorioretinal scars.

ETIOLOGY

Infection or recurrence of infection caused by parasite *T.gondii*; natural host is the cat; human is the intermediate host.

EPIDEMIOLOGY

- Congenital infection
Most common.
Most severe disease if contracted in the first trimester. Transmission is the greatest in the third trimester, with multisystem involvement and usually bilateral ocular disease.
- Acquired infection
Ingestion of oocytes or tissue cysts in previously unexposed host. Cysts found in undercooked meat, poorly cleaned vegetables from contaminated soil.
Transmitted from fecal-oral contamination by being licked by a cats tongue.

SIGNS AND SYMPTOMS

Blurred vision. FLOATERS

Photophobia. REDNESS, PAIN IF ANTERIOR UVEITIS ASSOCIATED

DEMOGRAPHICS

Otherwise healthy patients.
AIDS patients

OPHTHALMIC FINDINGS

▲ Congenital

- Microphthalmia
- Nystagmus
- Coloboma
- Strabismus
- Ptosis
- Macular scars (Fig. 4.18)

▲ Acquired or reactivation

- USUALLY Granulomatous iridocyclitis SOMETIMES MAY PRESENT WITH STELLATE KPs Necrotizing retinitis (Fig. 4.19) adjacent to large, atrophic yellow-white, unevenly pigmented chorioretinal scar.
- Severe vitritis, "headlight in the fog" (CLASSIC APPEARANCE (Fig. 4.20))
- Periphlebitis
- Papillitis
- Branch retinal vein occlusion (BRVO)
- Diffuse retinitis
- Gray-white punctate lesions in the outer retina and RPE
- More than one-third of cases have macular involvement.
- Immunosuppressed patients may have atypical presentations which may resemble CMV retinitis

SYSTEMIC FINDINGS

CNS toxoplasmosis IN AIDS PATIENTS ALSO MYOCARDITIS,
PNEUMONIA.

IMMUNOCOMPETENT PATIENTS - LESS THAN 1% DEVELOPS
SYSTEMIC DISEASE - USUALLY LYMPHADENOPATHY

SEROLOGIC TESTING

Serum sample with immunoglobulin M (IgM) to *T. gondii*, or threefold rise in immunoglobulin G (IgG); IgG is always positive. Low titer is diagnostic in case of retinal lesion.

DISEASE COURSE

- Recurrence after cessation of treatment may occur and maintenance prophylaxis is recommended in AIDS patients.

Fig. 4.18 Congenial quiescent, mature, hyperpigmented toxoplasmal macular scar

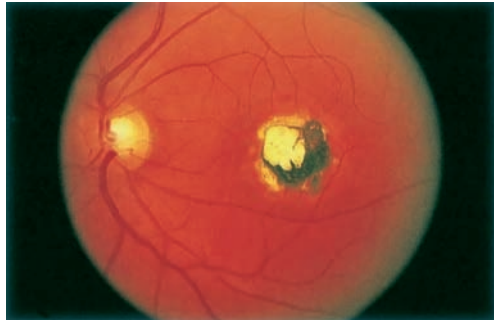


Fig. 4.19 Toxoplasmosis, acute retinal necrosis following periocular corticosteroid injection.

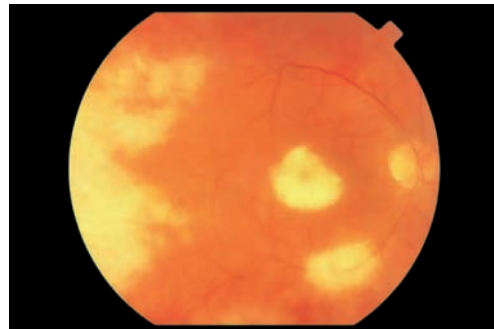
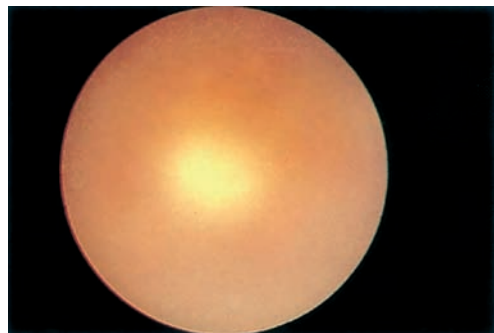


Fig. 4.20 *Toxoplasma* retinochoroiditis, “headlight in the fog”



- Complications: branch retinal artery occlusion (BRAO), glaucoma, cystoid macular edema, cataracts, tractional retinal detachment, optic atrophy, epiretinal membrane, serous retinal detachment.

TREATMENT

- Small active peripheral lesion:
Observation
Treatment has not been shown to hasten resolution, but limit extent of scarring.
- Macula or optic nerve threatened or significant vitritis: the 6-week regimen:
Pyrimethamine (Daraprim) 75-100 mg/loading dose the first day, continued with 25-30 mg
Sulfadiazine (1g qid) or Bactrim BS (1 tab PO bid)
Folinic acid (3 times a week)
Check complete cell count and platelet weekly.
or
Clindamycin (300mg PO qid)
Sulfadiazine
or
Trimethoprim/sulfamethoxazole (Bactrim DS
Add clindamycin for lesions in the posterior pole

INTRAVITREAL CLINDAMYCIN 1mg in 0.1ml + DEXAMETHASONE 1,0mg in 0,1 ML +
SYSTEMIC MEDICATIONS (SULFA MAINLY).
- May add oral steroids (prednisone) 24 to 48 hours after starting antibiotics.
- Steroids are contraindicated in immunocompromised patients.

WARNING

Periocular Steroids injections are contraindicated bringing about an exacerbation of the process.

DIFFERENTIAL DIAGNOSIS

- Cytomegalovirus (CMV) retinitis: hemorrhages, less vitritis
- Focal infectious retinochoroiditis (TB, syphilis)
- Sarcoidosis
- Lymphoma ▼

4. 2.2 BEHCET'S DISEASE

Behcet's disease is a multisystem syndrome consisting of an occlusive vasculitis, oral and genital ulceration, and arthritis predominantly affecting Mediterranean including Armenian and Japanese patients.

ETIOLOGY

Unknown. Associated with HLA-B5, HLA-B51 (ocular), HLA-B12 (oral and skin),

EPIDEMIOLOGY

- Highest prevalence in Asia (Japan) and Middle East (Turkey).
- Male patients affected more often than female patients
- Peak age: 25 to 40 years

SIGNS AND SYMPTOMS

Decreased vision, photophobia

OCULAR FINDINGS

- Found in 70% to 90% of patients, usually follows systemic disease
- Bilateral uveitis in 80%

▲ Anterior uveitis

Bilateral non-granulomatous iridocyclitis
Hypopion, shifts with gravity (Fig. 4.15)

Posterior synechiae
Iris atrophy
Peripheral anterior synechiae

▲ **Posterior uveitis**

Occlusive retinal vasculitis (Fig. 4.21)
Recurrent vascular occlusions
Cotton-wool spots
Optic nerve edema
Neovascularization
Vitreous hemorrhage

SYSTEMIC FINDINGS

Oral or mucous membrane ulcers (Fig. 4.22)
Erythema nodosum
Thrombophlebitis
Arthritis
Large vessel vasooclusion
CNS-Behcet's disease: most patients do not have ocular disease

DIFFERENTIAL DIAGNOSIS

Sarcoidosis: oral ulcers, arthralgia, retinal vasculitis
Reiter syndrome: HLA-B27 positivity, anterior uveitis, conjunctivitis, oral ulcers, arthritis, urethritis.
Viral, Crohn's disease, collagen-vascular disease (SLE, etc.).

SPECIAL TESTS - HLA typing:

- May be helpful in incomplete, suspect, and possible forms
- Erythrocyte sedimentation rate (ESR), C-reactive protein, ANA: abnormal in some cases.
- Pathergy: skin-prick test with formation of blister after 24 to 48 hours

TREATMENT

Topical and systemic steroids.

Low threshold for systemic immunosuppression with agents such as cyclosporine A, methotrexate, chlorambucil, cyclophosphamide, when retinal vasculitis present.

Posterior sub-Tenon's or intravitreal steroid injections for cystoid macular edema.

COMPLICATIONS

Cataracts, glaucoma, optic atrophy, RD, cystoid macular edema.

DISEASE COURSE AND PROGNOSIS

- Symptoms recur every 1 to 2 mo with exacerbations and remissions
- Poor prognosis if posterior segment involved, with 25% to 50% of patients legally blind in 4 years.
- Good prognosis if solely anterior uveitis.
- With CNS involvement, up to 40% mortality. ▼

Fig. 4.21 Behçet syndrome, retinal vasculitis

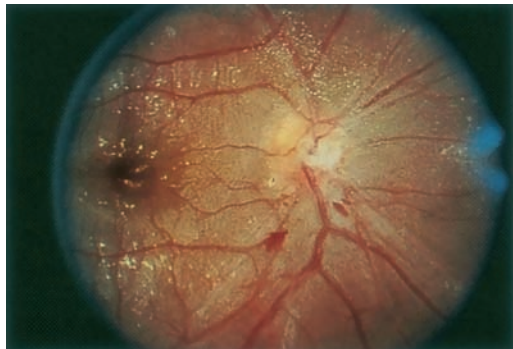
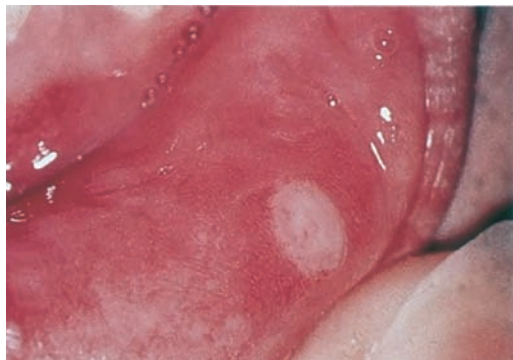

Fig. 4.22 Behçet syndrome, mucous membrane ulcers



4. 2. 3 SYMPATHETIC OPHTHALMIA

Sympathetic ophthalmia is a bilateral non-necrotizing granulomatous panuveitis that may occur following penetrating ocular trauma or intraocular surgery (Fig. 4.23).

TERMINOLOGY

Inciting eye: eye sustaining penetrating trauma.

Sympathizing eye: fellow, uninjured eye, which develops inflammation.

EPIDEMIOLOGY

- Interval from insult to disease in 65% within 2 mo., 80% within 3 mo., and 90% within 1 year; range is 5 days to 50 years.
- Occurs in approximately 1.9/1,000 cases of penetrating ocular trauma and 1/10,000 cases of intraocular surgery.

PATHOGENESIS

Uveal pigment serves as an antigen for cell-mediated immune response.

SIGNS AND SYMPTOMS

Blurred vision

Redness

Photophobia in the sympathizing eye.

Decreased accommodation

OPHTHALMIC FINDINGS

Persistent granulomatous inflammatory reaction

Mutton fat keratitic precipitates

Vitritis

Choroidal infiltrates

Papillitis

Dalen-Fuchs nodules (yellowish infiltrates at the level of the RPE/ Bruch's membrane) in 25% to 40% cases (Fig. 4.24)

Chronic inflammation of the itching eye.

DIFFERENTIAL DIAGNOSIS

Lens-induced uveitis

Occult perforation

Endophthalmitis in the early post-traumatic or post-surgical setting

Sarcoidosis

Vogt-Koyanagi-Harada syndrome: usually has associated systemic symptoms

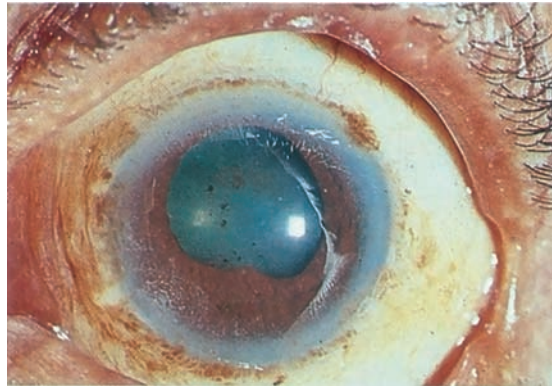


Fig. 4.23 Sympathetic ophthalmia, sympathizing eye with synechiae

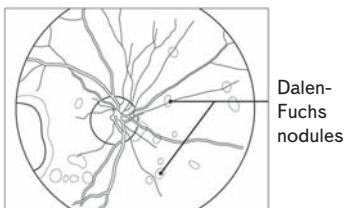
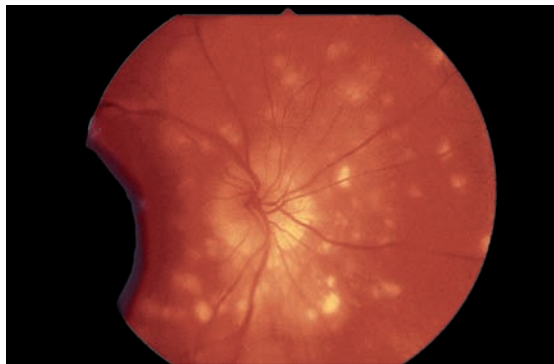


Fig. 4.24 Dalen-Fuchs nodules.
Sympathetic ophthalmia



SPECIAL TESTS

ERG - subnormal early finding

TREATMENT:

- Classic teaching: Enucleation of the traumatized eye within 2 weeks after the injury (if there is no vision or there is irreparable damage) may prevent the onset of sympathetic ophthalmia.
- If the inflammation has already started (bilateral uveitis), the traumatized eye should not be removed as finally it may end up with better vision than other eye.
- Systemic steroids (Prednisone 1 to 1.5 mg/kg per day).
- For refractory cases use cyclosporine A or chlorambucil.

PROGNOSIS

Sixty-five percent achieve acuity better than 20/60 in sympathizing eye following treatment. ▼

5.1 CONGENITAL CATARACT

Congenital opacity of the crystalline lens usually categorized by etiology or location, often bilateral, central polar plaques. These can usually be easily seen by examining the child in a darkened room from a distance of 1 meter using a direct ophthalmoscope focused to get a good red reflex. The cataract appears as a darkened central opacity. These plaques often do not expand in size and are an opacification of the defect left by the embryologic vessel that often results in the much more frequently seen Mittendorf dot. Cataract extraction in these patients, at any age, is far more hazardous as there is often a hole in the capsule that the plaque covers and when the plaque is removed, vitreous prolapses occur.

ETIOLOGY

- Hereditary or Syndromes (with or without chromosomal abnormalities)
- Intrauterine Infections (rubella, varicella)
- Ocular disorders (persistent hyperplastic primary vitreous, Leber's congenital amaurosis, retinopathy of prematurity)
- Other (birth trauma, idiopathic, and maternal drug ingestion)

EPIDEMIOLOGY

Congenital cataracts occur in approximately 1 of 2000 live births.

SYMPTOMS

- Decreased vision
- May notice white pupil and eye turn

SIGNS

- Decreased visual acuity
- Leucocoria
- Amblyopia
- Possibly strabismus (usually with unilateral cataracts)
- Nystagmus (usually does not appear until 2-3 mo of age; rarely when cataracts develop after age 6 mo).

TYPES

CAPSULAR

Opacity of the lens capsule, usually anteriorly.

LAMELLAR or ZONULAR (Fig. 5.1)

Central, circumscribed opacity surrounding the nucleus

LENTICULAR or NUCLEA (Fig. 5.2)

Opacity of the lens nucleus

POLAR (Fig 5.3)

Central opacity located near the lens capsule, anteriorly or posteriorly

See above for a description of the dangers of this type.

SUTURAL (Fig. 5.4)

Opacity of the Y-shaped sutures in the center of the lens.

MANAGEMENT

- Dilation with tropicamide 1% t.i.d. may be applied as a temporary measure before surgery to allow light to pass around the cataract; however surgery should not be delayed.
- If cataract obscures the visual axis (media opacity >3 mm) or is causing secondary ocular disease (glaucoma or uveitis), cataract extraction should be performed within days to a week after diagnosis in infants because delay may lead to amblyopia; postoperatively, the child requires proper aphakic correction with contact lens or spectacles if bilateral; depending on age and etiology. IOL implantation should be strongly considered as the primary method to prevent lifelong amblyopia.

AMBLYOPIA

- ▲ If the cataract is not causing amblyopia, glaucoma, or uveitis, the child is observed closely for progression

▲ Patching or occlusion therapy for amblyopia

Get a B-scan ultrasound on those eyes with a unilateral white pupil even if cataract appears to be the Dx. Also for a unilateral dense cortical cataract that obscures the peripheral retinal view.

Remember that the cause for cataract can be a retinoblastoma in the periphery. It should be ruled out before the cataract surgery. ▼

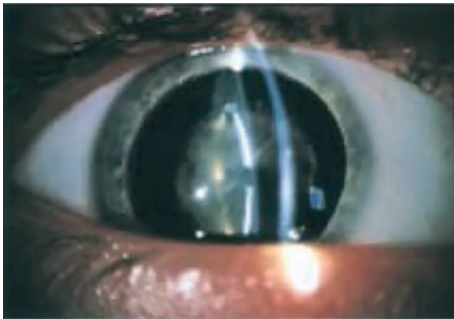


Fig. 5.1 Zonular cataract

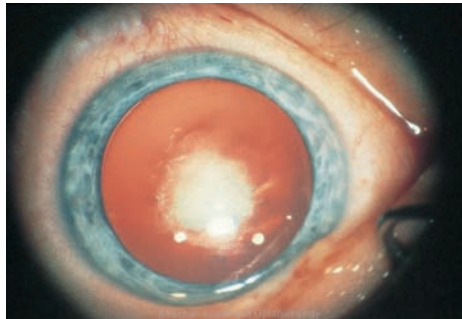


Fig. 5.2 Nuclear cataract

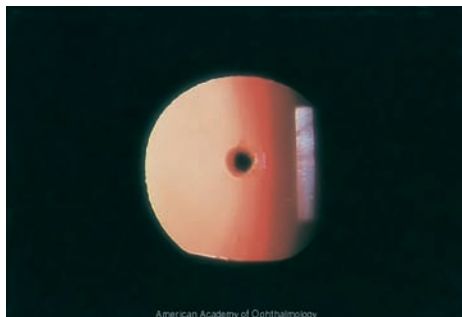
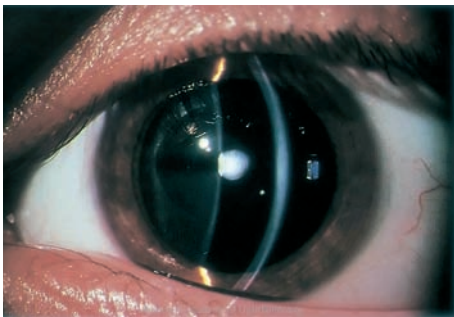


Fig. 5.3 Anterior polar (A) Anterior polar cataract viewed by retroillumination (B)

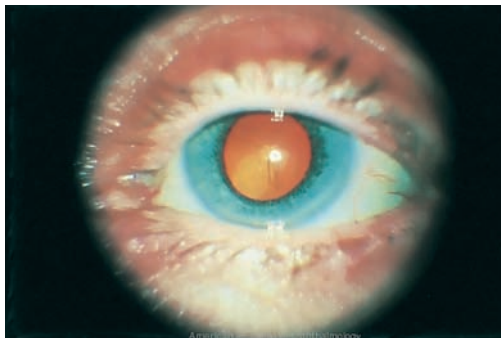


Fig. 5.4 Satural cataract

PROGNOSIS

Depends on age and duration of visually significant cataract prior to surgery; poor if amblyopia exists. Amblyopia prognosis depends upon the age of the child when the diagnosis is made.

5. 2 ACQUIRED CATARACT

Lenticular opacity usually categorized by etiology or location.

ETIOLOGY

- **Age-related** (most common)
- Trauma (ocular or head contusion, electrocution, etc. (Fig. 5.5))
- After previous vitrectomy for any reason. Surgery for these patients is of a greater degree of difficulty due to the loss of zonular elasticity.
- **Drug-Induced**, Toxic {Steroids, anticholinesterases (miotics), antipsychotics (phenothiazines) (Fig. 5.6), amidarone, chemicals
- Intraocular inflammation (uveitis,etc.)
- Radiation
- Intraocular tumor
- Degenerative ocular disease (retinitis pigmentosa)
- Diabetes

The juvenile form is characterized by white "snowflake" opacities in the anterior and posterior subcapsular locations (Fig. 5.7). It often progresses rapidly.

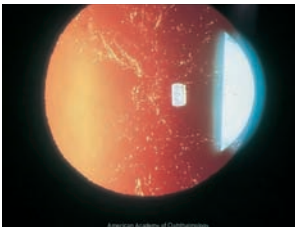


Fig. 5.5 Electrical injury

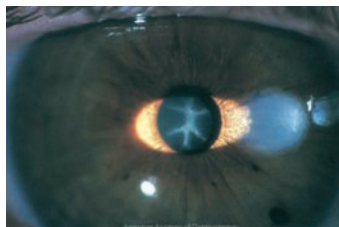


Fig. 5.6 Pigmental deposits on anterior lens capsule in patient treated with phenothiazines

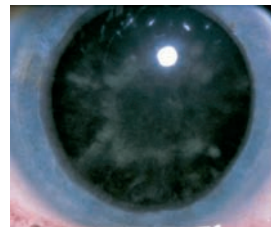

Fig. 5.7 Diabetic cataract, also called snowflake cataract, consists of gray-white subcapsular opacities

Adults develop age-related cataracts as described previously, but at an earlier stage.

- Others (hypocalcemia, Wilson disease, myotonic dystrophy, atopic dermatitis)

SYMPTOMS

- Slow progressive visual loss or blurring, usually over months to years, affecting one or both eyes..
- Glare, particularly from oncoming headlights while driving at night or driving into the sun.
- Difficulty reading with the impression that glasses are constantly "dirty", especially true among those with posterior subcapsular type cataracts.
- Reduced color perception.

The particular symptoms are based on the location and density of the lens opacity..

SIGNS

- Opacification of the normally clear crystalline lens
- Decreased red reflex
- The retina, optic nerve and vessels often appear indistinct.
- Myopic shift (The patient may be found to be more myopic than previously noted (so-called "second sight").

TYPES

1. NUCLEAR (Fig. 5.8)

Yellow or brown discoloration of the central part of the lens on slit-lamp examination. Typically blurs distance vision more than near vision.

2. POSTERIOR SUBCAPSULAR (Fig. 5.9)

Opacities appear near the posterior aspect of the lens, often forming a plaque. They are best seen in retro-illumination against a red fundus reflex. Glare and difficulty reading are common complains.

- Ocular inflammation
- Prolonged steroid use
- Diabetes
- Trauma
- Radiation

Classically occurs in patients younger than 50 years.

3. CORTICAL (Fig. 5.10)

Radial or spokelike opacities in the lens periphery that expand to involve the anterior and posterior lens. Often asymptomatic until the changes develop centrally and then complaints of diplopia are described.

POINTS TO REMEMBER

A mature cataract is defined as lens anterior cortical changes sufficiently dense to obscure totally the view of the posterior lens and posterior segment of the eye.

WORK-UP

Determine the etiology, whether the cataract is responsible for the decreased vision, and whether surgical removal would improve vision.

1. History:

Medications?

Systemic diseases?

Trauma?

Ocular disease or poor vision in youth or young adulthood (before the cataract)?

2. Complete ocular examination, including distance and near vision, pupillary examination and refraction.

A dilated slit-lamp examination by using both direct and retro-illumination techniques is usually required to view the cataract properly.

Fundus examination, concentrating on the macula, is essential in ruling out other causes of decreased vision. It is helpful for preoperative planning to note the degree of pupil dilation, density of the cataract, and presence or absence of pseudoexfoliation syndrome or phacodonesis.

3. B-scan ultrasonography or OCT when the fundus is obscured by a dense cataract to rule out posterior segment disease.

4. The potential acuity meter (PAM) or laser interferometry can be used to estimate the visual potential when cataract extraction is being considered in an eye with posterior segment disease, but often overestimate the eye's visual potential in the presence of macular holes or macular pigment detachment. Near vision is often the most accurate manner of evaluating macular function if the cataract is not too dense.

Super Pinhole

A useful inexpensive device to determine the retina potential is to place a +10 lens in front of a multipinhole device in the patient whose eye has been dilated. A reading card is then brought to within 10 centimeters of the eye with the other eye covered and the patient asked to read the line of print. Usually readings are one or two lines better than post op results but still give a good assessment of function.

- When surgery is planned, keratometry readings and A-scan ultrasonography measurement of axial length are required for determining the power of the desired intraocular lens (IOL). An evaluation of the corneal endothelium is usually done at the slit-lamp. ▼

Fig. 5.8 Nuclear cataract viewed with diffuse illumination (left) and with a slit beam (right)

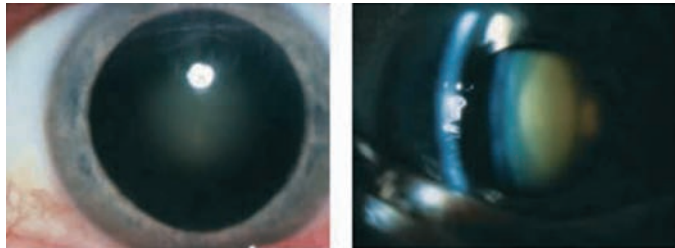


Fig. 5.9 Posterior subcapsular cataract viewed at the slit lamp (left) and with indirect illumination (right)

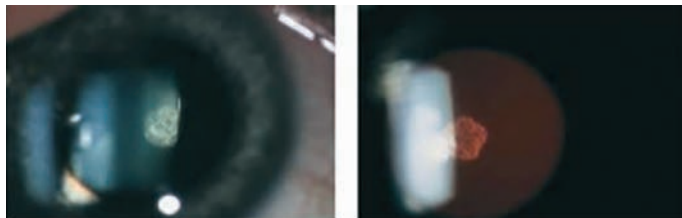
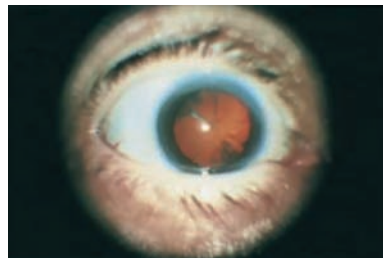


Fig. 5.10 Cortical cataract (cuneiform opacities) viewed by retroillumination



5.3 PSEUDOEXFOLIATION SYNDROME

Abnormal fibrillar material is produced and deposited on the anterior lens capsule, iris, and other ocular structures.

Open-angle glaucoma and weakened zonules are frequently found in these patients. Surgery in these patients should be done earlier to prevent the danger of zonular dehiscence intra operatively. Use of a capsular tension ring is routinely used and provides greater safety in cases where zonules have already dehisced from a quadrant. If more than half of the zonules have dehisced prior or during surgery, intracapsular cataract surgery is recommended with an anterior chamber lens or posterior chamber lens with both haptics sutured to the iris.

ETIOLOGY

Abnormal pseudoexfoliative material deposited on the anterior lens capsule, posterior iris, cornea, and within the trabecular meshwork (Fig. 5.11).

SIGNS AND SYMPTOMS

Usually none

OPHTHALMIC FINDINGS

- Lens subluxation or dislocation
- Anterior capsular opacification or peeling, or both, often in a bull's-eye configuration.
- Open-angle glaucoma.

A poorly dilating pupil will make for greater complexity during surgery.

SYSTEMIC FINDINGS

Pseudoexfoliative material has been found systemically in multiple organs of patients with this disease, usually of no consequence.

DISEASE COURSE

- Glaucoma may develop in 40% to 60% of patients.
- Spontaneous lens subluxation may develop in 5% of patients.

TREATMENT AND MANAGEMENT

- CATARACT EXTRACTION WITH CAREFUL ATTENTION TO PREVENT

Fig. 5.11 Exfoliation syndrome (pseudoexfoliation)

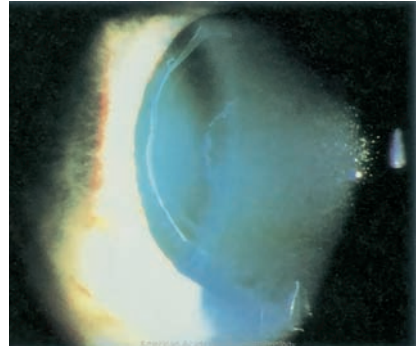
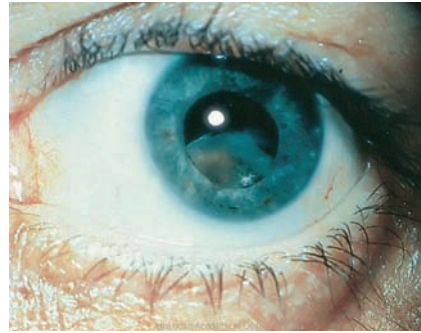


Fig. 5.12 Dislocated cataractous lens following blunt trauma



ZONULAR DISRUPTION

- VITREOUS LOSS IS FIVE TIMES MORE FREQUENT IN THIS GROUP OF PATIENTS
- REGULAR MONITORING OF INTRAOCULAR PRESSURE

Allow a greater time for pupil dilation with the use of Tropicamide 1%, Cyclopentolate 1%, Neosynepherine 2.5% (10% if not hazardous to blood pressure) and Atropine 1% all repeated every 10 minutes starting 40 minutes prior to surgery.

Use preserved epinepherine in the saline or a balanced salt solution drip running into the eye during surgery. May need pupillary expanders to provide adequate exposure.▼

5.4 TRAUMATIC LENS SUBLUXATION AND DISLOCATION

Blunt ocular trauma can cause stretching of the zonular ring, stretching and rupture of the lens zonules, and lens subluxation (Fig. 5.12).

ETIOLOGY

Concussive force transmitted to the lens with zonular disruption.

SIGNS AND SYMPTOMS

Monocular diplopia

OPHTHALMIC FINDINGS

- Phacodonesis
- Irididonesis
- Torn zonules, subluxated lens
- Traumatic cataract
- Comotio retinae
- Retinal dialysis
- Rhegmatogenous retinal detachment
- Hyphema
- Poor view of fundus due to comotio retinae or corneal edema

SYSTEMIC FINDINGS

Related to trauma

Periorbital trauma (eyelid ecchymosis, bone fractures)

DISEASE COURSE

- Progression of cataract
- May have progressive subluxation of lens

REATMENT AND MANAGEMENT

- Surgical removal of cataract (intracapsular or pars plana approach if inadequate zonular support) see above
- Thorough examination of peripheral retina. ▼

5.5 MANAGEMENT AND TREATMENT IN ACQUIRED CATARACT

1. Cataract surgery may be performed for the following reasons:

MEDICAL

- To improve visual function in patients with symptomatic visual disability.
- As surgical therapy for ocular disease (e.g. lens-related glaucoma or uveitis).
- To facilitate management of ocular disease (e.g. to monitor or treat diabetic retinopathy or glaucoma).

COSMETIC

- To obtain a black pupil in case of poor prognosis for postoperative vision.
- 2. To correct any refractive error if the patient declines cataract surgery.
- 3. A trial of mydriasis (e.g. tropicamide 1% with or without phenylephrine 2.5% q.d.) may be used successfully in some patients if the patient desires non-surgical treatment. The benefits of this therapy are only temporary.

FOLLOW-UP

Unless there is a secondary complication from the cataract (e.g. glaucoma; quite rare), a cataract itself does not require urgent action.

Patients who decline surgical removal are re-examined yearly, and sooner if there is a symptomatic decrease in visual acuity. ▼

5.6 CATARACT SURGERY TIMING

Cataract extraction is advised if the patient is subjectively disturbed by his or her condition in daily life.

In general, it is a very individual decision (e.g. someone driving a lot at night might have cataract extraction at an earlier stage than another). ▼

5.7 LENS-INDUCED SECONDARY GLAUCOMA

Secondary glaucoma due to lens-induced abnormalities.

MECHANISM

LENS PARTICLE- PHACOANTIGENIC UVEITIS (Fig. 5.13)

Retained cortex or nucleus after cataract surgery or penetrating trauma causes inflammatory reaction and obstructs trabecular meshwork; more anterior segment inflammation than phacolytic.

PHACOLYTIC (Fig. 5.14)

Lens proteins from hypermature cataract leak through intact capsule and are ingested by macrophages; can occur with intact, dislocated lens; lens proteins and macrophages obstruct trabecular meshwork.

PHACOMORPHIC (Fig. 5.15)

Enlarged, cataractous lens pushes the iris forward, causing secondary angle-closure.

SYMPTOMS

- Decreased vision
- Pain
- Photophobia
- Red eye
- Possibly halos around lights and signs of angle-closure.
- Decreased visual acuity
- Increased intraocular pressure
- Ciliary injection
- Anterior chamber cells and flare
- Peripheral anterior synechiae
- Cataract or residual lens material
- Signs of recent surgery or trauma including surgical wounds, sutures, and signs of an open globe in case of phacoantigenic uveitis.

DIFFERENTIAL DIAGNOSIS

- Uveitis
- Endophthalmitis

WORK UP

- Complete ophthalmic history and eye examination with attention to cornea, tonometry, anterior chamber, gonioscopy, iris, lens, and ophthalmoscopy.
- B-scan ultrasonography and OCT if unable to visualize the fundus.

MANAGEMENT AND TREATMENT

- Topical steroid (prednisolone acetate 1% up to q1h) and cycloplegic agent (cyclopentolate 1% b.i.d. to t.i.d.)
- Medical treatment of increased intraocular pressure.
Definitive treatment consists of surgical lens extraction or removal of retained lens fragments.
- May require glaucoma filtering procedure.

PROGNOSIS

Good if definitive treatment is performed early and pressure control is achieved. ▼

Fig. 5.13 Lens particle glaucoma. Cortical lens material obstructs the trabecular meshwork following traumatic disruption of the anterior lens capsule

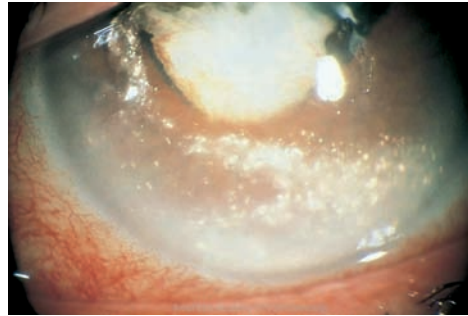


Fig. 5.14 Phacolytic glaucoma

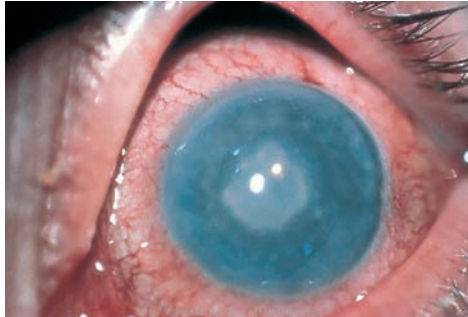
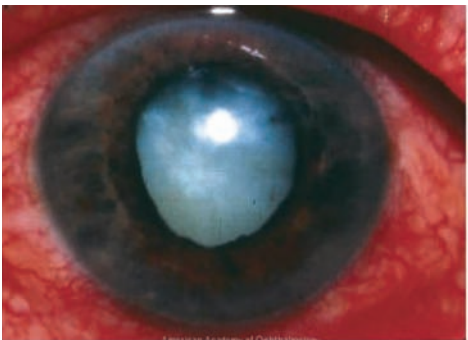


Fig. 5.15 Phacomorphic glaucoma



5.8 ANESTHESIA FOR CATARACT SURGERY

Anesthetic techniques for cataract surgery have advanced significantly.

GENERAL ANESTHESIA

was preferred in past years.

- Current Indications:
- In children and most teenagers;
- In patients with:
 - dementia
 - mental retardation
 - uncontrollable cough
 - marked head tremor

LOCAL ANESTHESIA

RETROBULBAR anesthesia used with or without regional anesthesia of the facial nerve (Fig. 5.16)

Advantages:

- Excellent ocular akinesia and anesthesia:
- Ретробульбарное кровоизлияние
- Complications (uncommon):
 - Retrobulbar hemorrhage
 - Globe penetration
 - Optic nerve trauma
- Inadvertent intravenous injection associated with cardiac arrhythmias.
- Inadvertent intradural injection associated with seizures, respiratory arrest and brain stem anesthesia.

PERIBULBAR anesthesia via single or multiple injection sites using a shorter needle (Fig. 5.17)

Advantages

- Theoretically eliminates the complications of optic nerve injury and CNS side effects from intradural injection.

Disadvantages

- Slightly less effective than the retrobulbar for providing akinesia and anesthesia.
 - The onset is slower
 - The risk of globe penetration is not eliminated.
- Variations of peribulbar anesthesia include Subtenon and subconjunctival injections.

TOPICAL ANESTHESIA

Due to marked improvements in surgical technique, the technique of topical anesthesia has been popularized as " phaco anesthesia " Topical anesthesia includes eye drop application, sponge anesthesia, eye drops and intracameral injection, and most recently a combination of viscoelastic and anesthetic agent termed viscoanesthesia.

Advantages

- Decreased risk of ocular perforation
- Reduced need for intravenous sedation in some patients
- Diplopia is eliminated because no ocular muscle akinesia is done
- No patching because there is no eyelid block.

Disadvantages

- Patient cooperation is mandatory.
- Instillation of topical anesthetics alone may be insufficient in some cases.
- Additional use of intracameral non-preserved lidocaine.

PATIENTS NONELIGIBLE FOR TOPICAL ANESTHESIA

- Significant hearing impairment
- Language barrier
- Emotional inability to cooperate with the procedure
- Blepharospasm

- Significant head tremor
- Nystagmus
- Anticipated prolonged or complex surgery

POINTS TO REMEMBER

- For Anterior Chamber instillation only NONPRESERVED 1% Lidocaine should be used, as some preservative agents can be toxic to intraocular structures.
- Possible transient amaurosis due to direct retinal effect following intracameral anesthetics, more common in patients with open post capsules or previous vitrectomy. ▼

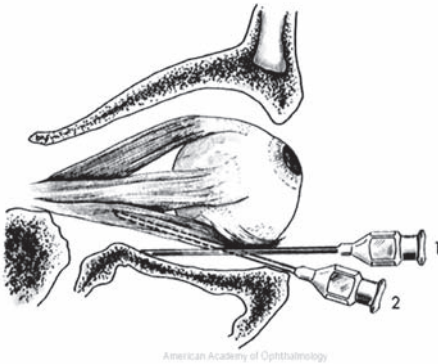


Fig. 5.16 Retrobulbar injection. If the top of the needle strikes the floor of the orbit as it is inserted (1) it is withdrawn slightly and redirected more superiorly (2)

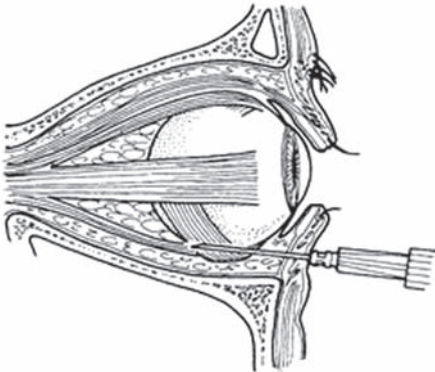


Fig. 5.17 Prebulbar anesthesia. 27-gauge sharp disposable needle passes backward in a sagittal plane and parallel to the orbit floor

5.9 CATARACT

TECHNIQUES FOR CATARACT SURGERY

Ophthalmic surgeons have witnessed a significant evolution in surgical techniques for cataract extraction in the 20th century.

INTRACAPSULAR CATARACT EXTRACTION (ICCE)

In intracapsular cataract extraction the lens is removed in-toto through a 180 degree corneal limbal incision using a cryoprobe or a capsule forceps (Fig 5.18).

This technique has almost entirely been replaced by extracapsular cataract extraction (ECCE).

EXTRACAPSULAR CATARACT EXTRACTION (ECCE)

In ECCE, only the opaque lens material is removed, leaving the capsular bag in place and enabling intracapsular IOL fixation. In planned ECCE, the nucleus is expressed in-toto and the cortex removed via an irrigation/aspiration system. Planned ECCE has almost been replaced by phacoemulsification.

In developing countries where the costs associated with Phako are too great, the nucleus is often bisected and then broken still further to be removed by a loop, all through a small incision. Cortex is then removed in the traditional way with manual irrigation/aspiration and later an implant folded and inserted. This makes for a rapidly healing, small sutureless wound in the cornea or a frown incision in the sclera.

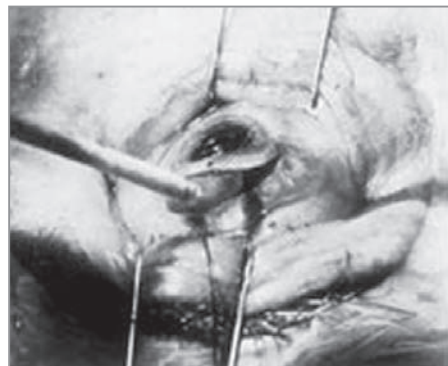

Fig. 5.18 Cryoextraction

PHACOEMULSIFICATION

Phacoemulsification ("phaco" meaning "lens" and "emulsify" meaning "to break into pieces") has gained popularity in recent years, and has become the most preferred method for cataract surgery in the industrialized world (Fig 5.19, 5.20).

Improvement in equipment and better control of fluidics facilitates a better AC stability, and control of post-occlusion surge. In phacoemulsification, the surgeon seated temporally first makes a clear corneal self-sealed incision and then makes a continuous, curvilinear capsulorhexis (CCC). Next, a small ultrasonic probe (Fig. 5.20) is inserted through the CCC and the probe's vibrating tip breaks up or "emulsifies" the cloudy lens into tiny fragments that are suctioned out of the capsule by an attachment on the probe tip. After the lens

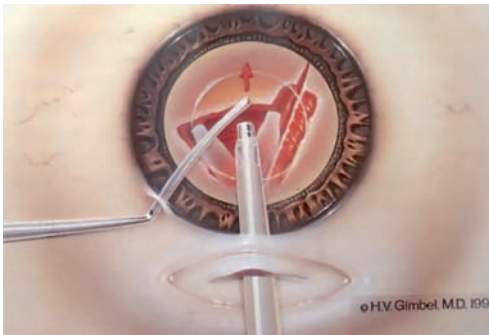

Fig. 5.19 Schematic phacoemulsification

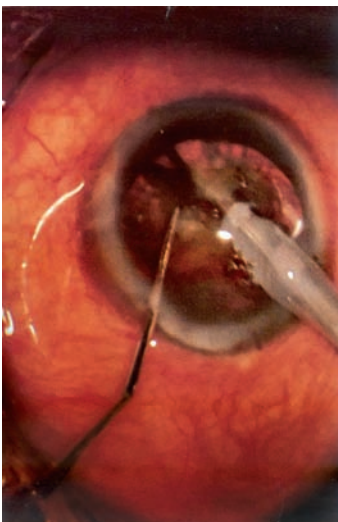


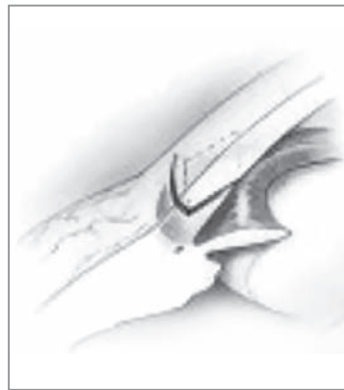Fig. 5.20 Phacoemulsification

is completely removed, the probe is withdrawn, leaving only the clear (now empty) bag-like capsule, which will act as support for the IOL. After viscoelastic injection into the anterior capsule and capsule, the foldable lens is usually implanted in the capsular bag using an injector. The viscoelastic is removed by irrigation/ aspiration and the wound hydrated with a #27 G needle to prevent leakage. The anterior chamber is tested for wound leakage, antibiotic drops are applied and the eye is patched.

**

The corneal wound (Fig 5.21) structure is made carefully using a keratome of 2.8 to 3.2 mm size. The tip is used to make a 10 micron curvilinear limbal incision. Next the keratome is inserted to the depth of the wound and advanced to create a square or rectangle with a long 3mm entry through the corneal stroma into the anterior chamber. ▼

Fig. 5.21 Corneal incision



5.10 POSTOPERATIVE CARE

Postoperative Care depends upon which method of surgery was chosen.

1. With ICCE or ECCE resulting in a large wound, healing occurs slowly over a 6- to 8-week period, but refractive changes due to further healing of the incision occur up to 9 mo. postoperatively. Non-absorbable sutures may be cut or removed if protruding or inducing astigmatism usually between 6 and 8 weeks; some are not removed. Phako or small incision sutureless ECCE wounds heal in one month. Patients can usually return to full activities within two weeks.
2. Postoperative medications usually include an antibiotic and steroid combination, which is continued for several weeks at the discretion of

the surgeon, e.g. Pred-Forte, Inflammase Forte or Maxitrol. It is better to keep the regime simple. The suggested regime is Steroid drops and Antibiotic drops (Ciloxan, Ocuflax, Zymer, Vigamox) 4 times a day (or 8 times a day if a long case) continuing for three weeks (or longer if a difficult case). They may be tapered off slowly over several weeks and are preferable to incorporating the use of FML. b.i.d.-q.i.d. 2-3 weeks and then a mild steroid (FML) qd for 3-4 weeks.

3. Restrictions on activity depend on the size of the incision and also should be individualized to the particular patient.

4. General medical considerations.

Constipation, coughing and sneezing should be avoided.

Anticoagulant therapy should be delayed for at least a few weeks. This is more dependent upon the method of anesthesia. Peribulbar anesthesia is most commonly used now, while retrobulbar anesthesia has not been done for years. Topical anesthesia is often done. Neither Topical nor Peribulbar anesthesia requires patients to discontinue their anticoagulants.

5. Follow-up appointments should generally occur at 1 day, 1 week, 3 weeks, and 6 weeks postoperatively, but also should be tailored to the particular setting.

"Cataracts removed earlier are removed easier"

Roger Ohanesian, MD ▼

5. 11 POSTOPERATIVE COMPLICATIONS

1. Cystoid Macular Edema (CME) (**Chapter 9 (9.5)**)
2. Endophthalmitis (**Chapter 15**)
3. Posterior Capsular Opacification (PCO) (**Chapter 5 (5.12)**) ▼

5.12 PCO SYNONYMS SECONDARY CATARACT, AFTER-CATARACT

SIGNS

1. Elschnig pearls (Fig. 5.22)

Abortive lens fiber formation by proliferation and migration of residual lens epithelium.

2. Fibrosis

- a. Fibrous layer central to capsule
- b. May produce wrinkling of capsule

MANAGEMENT/ TREATMENT

Surgical intervention

– Nd:YAG laser
capsulotomy

- a. Photodisruption of central posterior capsule
- b. Complications

1. IOL damage -pitting
2. Increase IOP - temporary
3. Retinal detachment ▼

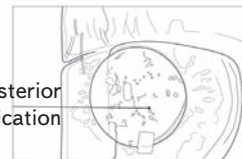
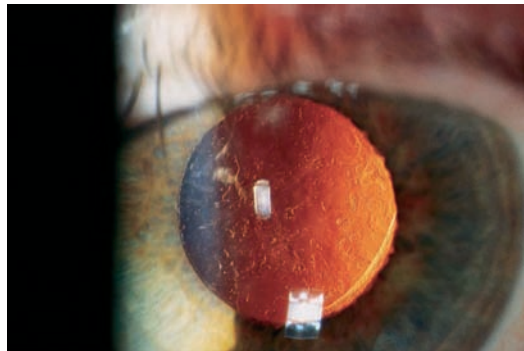


Fig. 5.22 Posterior capsular opacification

5.13 CATARACT SURGERY INDICATIONS

POINTS TO REMEMBER

1. A cataract alone DOES NOT CAUSE:

- ! -Acute vision loss
- Vision loss up to LP without projection or excentric vision
- A relative afferent pupillary defect

! **After a comprehensive examination one can conclude if the cataract is responsible for the decreased vision.**

Fundus examination, concentrating on the macula is essential in ruling out other causes of decreased vision.

Consider B-scan ultrasound when the fundus is obscured by a dense cataract to rule out posterior segment pathology.

2. Cataract surgery may be performed for the following reasons;

- a. To improve visual function in patients with symptomatic visual disability
- b. As surgical therapy of ocular disease (e.g., lens-related glaucoma or uveitis)
- c. To facilitate management of ocular disease (e.g. to monitor or treat diabetic retinopathy or glaucoma)

Capsular opacity is the most common cause of visual loss after cataract extraction.

In 15% to 50% of cases it typically occurs within 5 years after cataract surgery. ▼

6. VITREOUS

6. 1 VITREOUS HEMORRHAGE

SYMPTOMS

Sudden painless loss of vision or sudden appearance of black spots often associated with flashing lights..

CRITICAL SIGNS

In a severe vitreous hemorrhage the red fundus reflex may be absent (Fig. 6.1) and

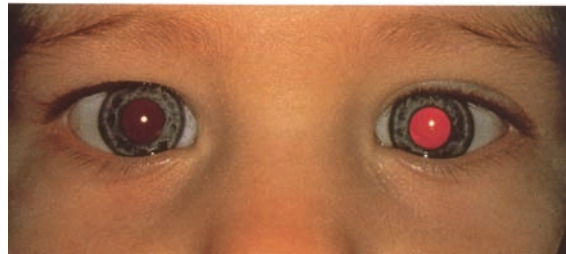


Fig. 6.1 Right eye Vitreous Hemorrhage

there may be no fundus visible on the ophthalmoscopy. Red blood cells can sometimes be appreciated when a slit lamp is focused posterior to the lens. In a mild vitreous hemorrhage blood may be seen to obscure part of the retina and retinal vessels.

Chronic vitreous hemorrhage has a yellow ochre appearance secondary to the breakdown of hemoglobin.

OTHER SIGNS

A mild afferent pupillary defect. Depending on the etiology there may be other fundus abnormalities.

ETIOLOGY

- Diabetic retinopathy (diabetic retinopathy is usually evident in the contralateral eye).
- Retinal break (commonly superior in cases of dense vitreous hemorrhage. This may be demonstrated by ultrasonography and scleral depression).
- Retinal detachment (may be diagnosed by ultrasound if the retina cannot be viewed on clinical examination).
- Retinal vein occlusion (usually a branch retinal vein occlusion).
- Commonly occurs in older patients with a history of high blood pressure. May have a history of a vein occlusion or sudden visual loss in the eye months to years previously.
- Posterior vitreous detachment. Common in middle-aged or elderly patients. Usually patients note floaters and flashing lights.
- Age-related macular degeneration (ARMD). Patients often acknowledge poor vision prior to the vitreous hemorrhages as a result of their underlying disease. Macular drusen and/or other findings of ARMD are found in the contralateral eye.
- Trauma to eye or abdomen (Purcell's Syndrome) by history.
- Intraocular tumor. May be visible on ophthalmoscopy or b-scan ultrasonography.
- Subarachnoid or subdural hemorrhage (Terson's syndrome). Frequently bilateral preretinal or vitreous hemorrhages may occur. A severe headache usually precedes the fundus findings. Coma may occur.
- Eales' disease. Usually occurs in men 20-30 years of age with peripheral retinal ischemia and neovascularization of unknown etiology. Decreased vision as a result of vitreous hemorrhage is frequently the presenting sign. The disease is often bilateral and is a diagnosis of exclusion.

POINTS TO REMEMBER

In infancy and childhood consider birth trauma, shaken baby syndrome, traumatic child abuse.

DIFFERENTIAL DIAGNOSIS

- **Vitritis (white blood cells in the vitreous).** The onset is rarely as sudden as in vitreous hemorrhage; anterior and posterior uveitis may also be present. No red blood cells and no hemorrhage in the vitreous are present.
- **Retinal detachment.** May occur without a vitreous hemorrhage, yet the symptoms may be identical. The fundus view may be difficult in a highly elevated detachment. In cases of highly elevated detachments slit-lamp examination may show the retina behind the lens.

WORK-UP

1. **History:** any ocular or systemic diseases, specifically the ones mentioned previously. Trauma.
2. Complete ocular examination, including a slit-lamp examination to check for iris neovascularization, intraocular pressure measurement, and a dilated fundus examination of both eyes using direct ophthalmoscopy.
3. When no retinal view can be obtained, a b-scan ultrasound is performed to detect an associated retinal detachment or intraocular tumor.

TREATMENT

1. If the etiology of vitreous hemorrhage is not known and a retinal break and/or retinal detachment cannot be ruled out (e.g. there is no known history of one of the diseases mentioned previously, there are no changes in the contralateral eye, and the fundus is obscured by a total vitreous hemorrhage) the patient is admitted to hospital or followed closely as an outpatient.

2. Bed rest with the head of the bed elevated (and sometimes bilateral patching) for 2-3 days (this reduces the chance of recurrent bleeding and allows the blood to settle inferiorly, permitting a view of the superior peripheral fundus, a common site for responsible retinal breaks).
3. Conservative treatment and follow-up is required for resolution of the vitreous hemorrhage, unless associated with a retinal tear or hole which needs to be treated immediately.
4. Eliminate aspirin, nonsteroidal anti-inflammatory drugs and other anticlotting agents unless they are medically necessary.
5. The underlying etiology is treated as soon as possible (e.g. retinal breaks are sealed with cryotherapy or laser photocoagulation (difficult to perform when the red blood cells are still in vitreous), detached retinas are repaired, and proliferative retinal vascular diseases are treated with laser photocoagulation or cryotherapy when there is no retinal view).
6. Surgical removal of the blood (vitrectomy) is usually performed by a retinal specialist for:
 - a. Vitreous hemorrhage accompanied by retinal detachment
 - b. Persistent vitreous hemorrhage for more than 3 months
 - c. Nonclearing diabetic vitreous hemorrhage for more than 1 month
 - d. Vitreous hemorrhage with neovascularization of the iris
 - e. Intractable increased intraocular pressure (hemolytic or ghost cell glaucoma)
7. Treat underlying medical condition.

FOLLOW-UP

The patient is evaluated daily for the first 2-3 days. If a total vitreous hemorrhage persists, and the etiology remains unknown, the patient is followed with a b-scan ultrasound every 1-3 weeks to rule out a retinal detachment. ▼

6.2 POSTERIOR VITREOUS DETACHMENT (PVD) (Fig. 6.2)

SYMPTOMS:

Floaters (“cobwebs” or “flies” that move with eye movement), blurred vision, flashes of light which are more common in dim illumination and are temporally located.

CRITICAL SIGNS:

One or more discrete pigmented vitreous opacities, often in the shape of a ring (Fig. 6.3), suspended over the optic disc. The opacities float within the vitreous as the eye moves from side to side.

OTHER SIGNS:

Vitreous hemorrhage, peripheral retinal and disc-margin hemorrhages, pigmented cells in the anterior vitreous, retinal break or detachment.

POINTS TO REMEMBER

The presence of pigmented cells in the anterior vitreous or vitreous hemorrhage in association with acute PVD indicates a high probability of a coexisting retinal break.

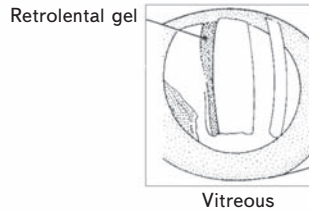
DIFFERENTIAL DIAGNOSIS:

▲ Vitritis

It may be difficult to distinguish PVD with pigmented anterior vitreous cells from vitreous inflammatory cells. In vitritis the vitreous cells may be found in both the posterior and anterior vitreous, the condition may be bilateral, and the cells are not typically pigmented. A history of uveitis may be elicited.

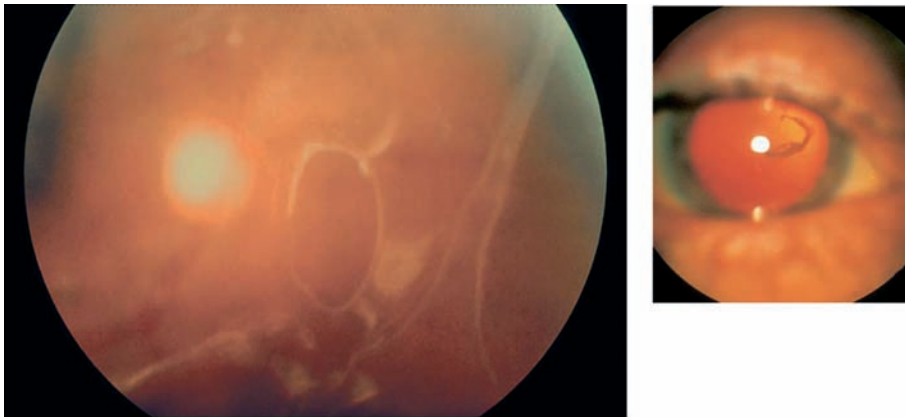
▲ Migraine

Patients complain of flashing lights in a fortified pattern that last approximately 20 minutes. A headache may or may not follow. No retinal or vitreous abnormalities are found on examination.



© 2005 Elsevier Ltd. Spalton et al: Atlas of Clinical Ophthalmology 3e

Fig. 6.2 Posterior vitreous detachment



© 2005 Elsevier Ltd. Spalton et al: Atlas of Clinical Ophthalmology 3e

Fig. 6.3 Weiss ring (annulus of vitreous condensation from around optic nerve) in vitreous

The following may occur with or without PVD, producing similar symptoms:

- Retinal break
- Vitreous hemorrhage
- Retinal detachment

WORK-UP

1. **History:** distinguish between the flashing lights of migraine, which typically occur in a “zig-zag” pattern, obstruct vision and last approximately 20 minutes, from the light sparks of PVD, which are commonly accompanied by floaters. Determine the duration of the symptoms.
2. A slit-lamp examination of the anterior vitreous, looking for pigmented cells.
3. Complete ocular examination by retinal specialist, particularly a dilated retinal examination using indirect ophthalmoscopy and scleral depression to rule out a retinal break and detachment.
4. PVD may be visualized by focusing in the vitreous, above the disc, using:
 - a. Indirect ophthalmoscopy
 - b. Direct ophthalmoscopy
The ophthalmoscope is initially focused on the cornea, the lens wheel is moved from a higher plus number toward a lower plus number, and the patient is asked to move his/her eye from left to right. The PVD is seen to float by.
 - c. A slit-lamp and a 60 or 90 diopter or Kruby lens examination.
Pull the slit-lamp back once focus on the disc is obtained. A black strand may be seen in the vitreous.

TREATMENT:

No treatment is indicated for PVD.

If a retinal break is found the patient should receive laser or cryotherapy within 24-72 hours to avoid development of a retinal detachment.

FOLLOW-UP:

The patient should be given the list of retinal detachment symptoms and told to return immediately if these symptoms develop:

- **an increase in floaters, or**

- **flashing lights, or**
 - **appearance of a curtain or shadow anywhere in the field of vision,an increase in floaters, or**
 - **flashing lights, or**
 - **appearance of a curtain or shadow anywhere in the field of vision,**
- ▲ If no retinal break or hemorrhage is found, the patient should be scheduled for repeat examination by a retinal specialist with scleral depression in 2-4 weeks, 2-3 months and 6 months after the symptoms first developed.
- ▲ If no retinal break is found, but mild vitreous hemorrhage or peripheral punctate retinal hemorrhages are present, repeat examinations are performed 1-2 weeks, 4 weeks, 3 months and 6 months after the event.
- ▲ If a vitreous hemorrhage dense enough to obscure the entire retina is found, ultrasonography is indicated to rule out a retinal detachment or tumor.

PATIENT INSTRUCTIONS:

Bed rest, with the head of the bed elevated, often with bilateral patches, is employed for 24-48 hours to hasten setting of the blood.▼

7. OPTIC NERVE DISEASES

7. 1 ANTERIOR ISCHEMIC OPTIC NEUROPATHY (AION) (Fig. 7.1)

Anterior ischemic optic neuropathy (AION) is an infarction of the optic nerve head just posterior to the lamina cribrosa due to inadequate perfusion by the posterior ciliary arteries resulting in acute loss of vision.

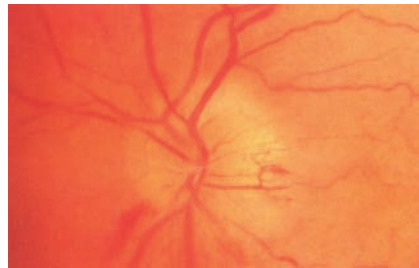


Fig. 7.1 Ant. Ischemic Optic Neuropathy (AION)

ETIOLOGY

Arteritic AION: giant cell arteritis (GCA)

Nonarteritic AION: associated with vasculopathic risk factor (hypertension, diabetes, atherosclerosis and collagen vascular disorders).

EPIDEMIOLOGY

Arteritic AION: usually seen in patients > 55 years old (mostly over 70); fellow eye involved in 75% of cases within 2 weeks without treatment; associated with polymyalgia rheumatica.

Nonarteritic AION: usually seen in younger patients; fellow eye involved in 25-40% of cases; associated with hypertension and diabetes mellitus.

SYMPTOMS:

Acute visual loss (arteritic > nonarteritic) and decreased color vision.

Patients with arteritic AION may also have:

- Headache
- Fever
- Malaise
- Weight loss
- Scalp tenderness
- Jaw claudication
- Amaurosis fugax
- Diplopia
- Joint pain
- Eye pain

SIGNS:

- Sudden, unilateral, painless decreased visual acuity and color vision.
- Positive afferent pupillary defect (APD)
- Altitudinal visual field defect most common; may be arcuate defect or central scotoma.
- Unilateral optic disc edema (often involving 1 sector); pallor or atrophy after 6-8 weeks.
- Fellow nerve often crowded with a small or absent cup
- Fellow nerve may be pale from prior episode (pseudo Foster-Kennedy syndrome)

Arteritic AION may also include:

- Swollen, tender temporal artery
- **Ophthalmic findings:**
 - ▲ cotton-wool spots
 - ▲ branch or central retinal artery occlusion
 - ▲ ophthalmic artery occlusion
 - ▲ anterior segment ischemia

WORK-UP

- ▲ Complete ophthalmic history and eye examination with attention to color vision, Amsler grid, pupillary reactions, and ophthalmoscopy.

- ▲ Check visual fields
- ▲ Special tests:
 - a. Erythrocyte sedimentation rate (ESR) and/or C-reactive protein test for GCA to rule out arteritic form: $ESR > [age / 2]$ in men and $> [(age + 10) / 2]$ in women is abnormal.
 - b. Temporal artery biopsy for GCA (beware: can get false-negative results from skip lesions); will remain positive up to 2 weeks after starting corticosteroids.
Medical consultation.

DIFFERENTIAL DIAGNOSIS

Inflammatory optic neuropathy
Infiltrative optic neuropathy
Compressive optic neuropathy

MANAGEMENT

ARTERITIC AION (Emergent Treatment)

- ▲ Systemic steroids (Methylprednisolone 1g IV qd in divided doses for 3 days, then prednisone 60-100 mg po qd with a slow taper; decrease by no more than 2,5 – 5,0 mg/wk); start before the results of the biopsy are known to prevent ischemic optic neuropathy in the fellow eye; follow ESR and the symptoms carefully.

NONARTERITIC

- ▲ Consider daily aspirin
- ▲ Treat underlying vasculopathic risk factors ▼

7.2 POSTERIOR ISCHEMIC OPTIC NEUROPATHY (PION)

Rarely, an ischemic infarction of optic nerve can occur in the retrobulbar portion causing posterior ischemic optic neuropathy (PION).

SYMPTOMS:

- Acute visual loss
- Decreased color vision

SIGNS:

- Sudden, usually bilateral, painless decreased visual acuity and color vision
- Positive APD
- Visual field defect (altitudinal or nerve fiber bundle defects) (Fig. 7.2)
- NORMAL OPTIC NERVE APPEARANCE (disc swelling may occur if the ischemic process extends anteriorly)

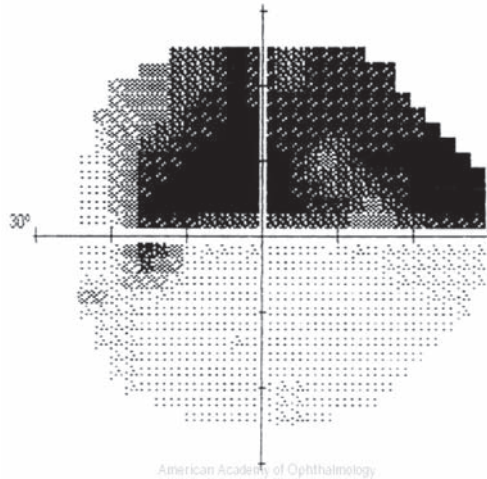


Fig. 7.2 Altitudinal defect, left eye

SYSTEMIC FINDINGS:

- Severe anemia and hypotension (major blood loss from surgery, trauma, GI bleeding, dialysis)
- Associated with medications (antibiotics [ethambutol, isoniazid, sulfonamides, chloramphenicol], anticancer drugs [cisplatin, vincristine, busulfan]).

TREATMENT

Treat the acute cause: prompt reversal of hypotension, blood transfusion. ▼

8. RETINAL VASCULAR DISEASES

8.1 CENTRAL RETINAL ARTERY OCCLUSION (CRAO) (Fig. 8.1)

Disruption of the vascular perfusion in the central retinal artery leading to global retinal ischemia.

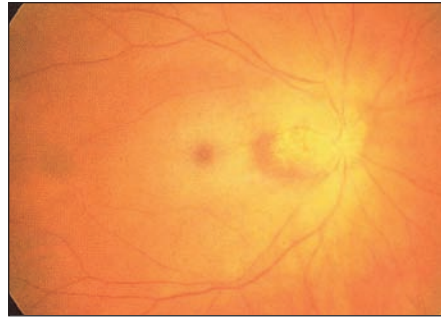

Fig. 8.1 Central Retinal Artery Occlusion (CRAO)

ETIOLOGY

Emboli (only visible in 20-40% of cases) or thrombus at the level of lamina cribrosa.

Other causes:

- Temporal arteritis
- Leukoemboli in collagen-vascular diseases
- Fat emboli
- Trauma (through compression, spasm or direct vessel damage)
- Hypercoagulation disorders
- Syphilis
- Mitral valve prolapse
- Particles (talc) from IV drug abuse
- Compressive lesions
- Primary open-angle glaucoma

EPIDEMIOLOGY

Usually occurs in elderly patients; associated with:

- hypertension
- carotid occlusive disease

- diabetes mellitus
- cardiac valvular disease

CRAO is more common than branch retinal artery occlusion (BRAO) or cilioretinal artery occlusion. Bilateral involvement is rare.

SYMPTOMS:

Sudden, unilateral, painless, profound loss of vision. May have history of amaurosis fugax (episodes of loss of vision), prior cerebrovascular accidents (CVA), or transient ischemic attacks (TIAs)..

SIGNS:

- Decreased VA in the count fingers (CF) to light perception (LP) range
- Positive APD
- Diffuse retinal whitening and arteriole constriction with segmentation (“box caring”) of blood flow
- Cherry-red spot in the macula (thin fovea allows visualization of the underlying choroidal circulation)

In ciliary retinal artery-sparing CRAO a small wedge-shaped area of perfused retina may be present on the temporal to the optic disc, spare the foveola, in which case visual acuity improves to 20/50 or better.

DIFFERENTIAL DIAGNOSIS

- Ophthalmic artery occlusion
- Comotio retinae
- Cherry-red spot due to inherited metabolic or lysosomal storage disease

WORK-UP

- ▲ Complete ophthalmic history and eye examination with attention to pupils, fundus examination.
- ▲ Check blood pressure.
In patients > 50 years old check erythrocyte sedimentation rate (ESR) to rule out arteritic ischemic optic neuropathy.

- ▲ Medical consultation for complete cardiovascular evaluation including electrocardiogram, echocardiogram, and carotid Doppler studies.

MANAGEMENT

OPHTHALMIC EMERGENCY

Treatment for central retinal artery occlusion should be immediate. Irreversible retinal damage is said to occur after 90 minutes, but treatment should be considered in patients presenting within 24 hours of onset. The goals of treatment are to restore retinal blood flow and to move a potential retinal embolus distally. Emergency treatment is initiated as follows:

1. Lower intraocular pressure to improve retinal perfusion in one or more of the following ways:
 - a) Massage the globe digitally and forcefully using enough pressure to dent a tennis ball. In addition to lowering the intraocular pressure, this might also dislodge an embolic plaque.
 - b) Administer acetazolamide (500 mg po).
 - c) Topical ocular hypotensive drops: b-blockers (Timolol 0,5% 1gtt q.15 min x 2, repeat as necessary).
 - d) Consider performing anterior chamber paracentesis.
2. Produce arterial dilation by having the patient breathe into a paper bag and consider admission to hospital for carbogen treatment (95% oxygen, 5% carbon dioxide for 10 minutes q.2h for 24-48 hours) to attempt to increase oxygenation and induce vasodilation.
3. IM injection of Papaverine 40 mg.
Unproven treatments include hyperbaric oxygen, antifibrinolytic drugs, retrobulbar vasodilators, and sublingual nitroglycerine.

If arteritic ischemic optic neuropathy is suspected: systemic steroids (Methylprednisolone 1g IV qd in divided doses for 3 days, then prednisone 60-100 mg po qd with a slow taper; decrease by no more than 2,5 – 5,0 mg/wk).

PROGNOSIS

Retinal pallor fades and circulation is restored over several weeks. Poor prognosis: most have persistent severe visual loss with constricted retinal arterioles and optic atrophy (positive APD). Rubeosis (20%) and disc or retinal neovascularization (2-3%) can occur. The presence of visible embolus is associated with increased mortality. ▼

8.2 CENTRAL / HEMIRETINAL VEIN OCCLUSION (CRVO/HRVO)

Occlusion of the central retinal vein (CRVO) usually caused by a thrombus in the area of the lamina cribrosa; hemiretinal occlusion (HRVO) (Fig. 8.2) occurs when the superior and inferior retinal drainage does not merge into a central retinal vein (20%) and is occluded (more like CRVO than BRVO).

ETIOLOGY

Associated with:

- Hypertension
- Coronary artery disease
- Diabetes mellitus
- Peripheral vascular disease
- Primary open-angle glaucoma (most commonly associated ocular disease).

Rarely associated with:

- Hypercoagulable states
- Hyperviscosity states, especially in bilateral cases
- Systemic lupus erythematosus
- Syphilis
- Sarcoidosis
- Malignancies (multiple myeloma, leucemia)
- External compression

In younger patients associated with:

- Oral contraceptive pills
- Collagen-vascular disease
- AIDS
- Protein S / protein C / antithrombin III deficiency or activated protein C resistance

EPIDEMIOLOGY**Usually seen in elderly patients (90% are >50 years old)**

- Slight male predilection

Two types: nonischemic (Fig. 8.3) and ischemic (Fig. 8.4).

Of the nonischemic cases, however, 54% later go on to develop ischemic CRVO.

Ischemic disease is more common in patients with cardiovascular disease.

YOUNGER PATIENTS CAN GET AN INFLAMMATORY CONDITION, TERMED PAPHILLOPHLEBITIS.

SYMPTOMS:

Sudden, unilateral loss of vision or, less frequently, history of transient obscuration of vision with complete recovery.

Some report pain and present initially with neovascularization of the iris and neovascular glaucoma following a loss of vision 3 months earlier ("90-day glaucoma"). Patients may have normal vision, especially when macula is not involved.

SIGNS:

- Decreased VA ranging from 20/20 to hand motion with most worse than 20/200;
- Dilated, tortuous retinal veins with superficial retinal hemorrhages and cotton-wool spots in all four quadrants extending to the periphery

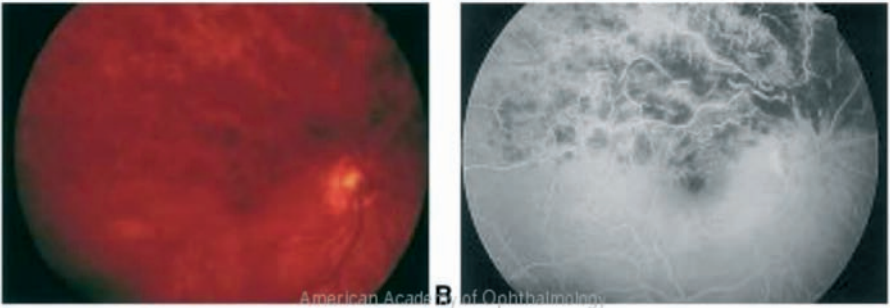


Fig. 8.2 Hemiretinal vein occlusion

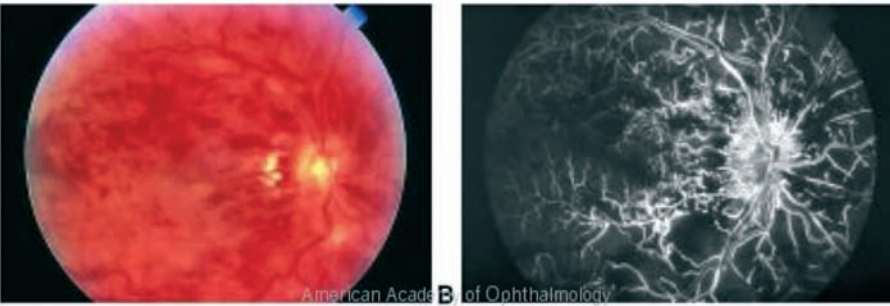


Fig. 8.3 Ischemic central retinal vein occlusion

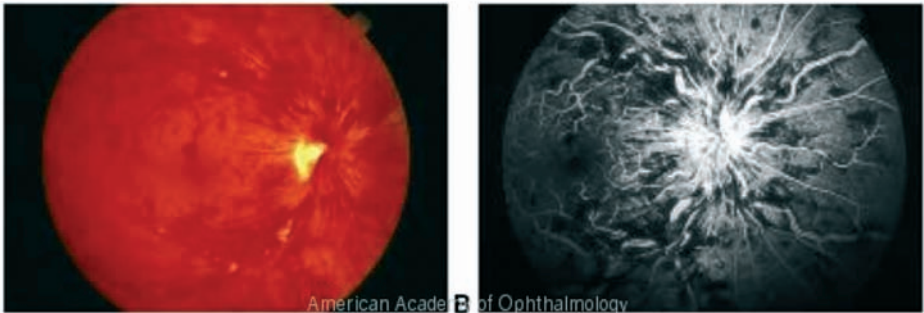


Fig. 8.4 Nonischemic central retinal vein occlusion

- Optic disc hyperemia
- Disc edema
- Macular edema
- Positive afferent pupillary defect (APD) possible but not in all cases

DEGREE OF DEFECT CORRELATES with AMOUNT of ISCHEMIA

Ischemic disease can produce:

- Rubeosis

- Disc or retinal neovascularization
- Neovascular glaucoma
- Vitreous hemorrhages

Collateral optociliary shunt vessels between retinal and ciliary circulation (50%) occur late. Transient patchy ischemic retinal whitening may occur early in nonischemic CRVO.

DIFFERENTIAL DIAGNOSIS

Hypertensive retinopathy,
diabetic retinopathy,
papilledema,
leucemic retinopathy,
retinopathy of anemia.

WORK-UP

- Complete ophthalmic history and eye examination with attention to pupils, tonometry, gonioscopy, ophthalmoscopy.
- Check blood pressure
- Lab tests: fasting blood glucose, complete blood count, ESR, coagulability
- FAG, ICG

POINTS TO REMEMBER

Initial poor visual acuity 20/200 or worse and a positive relative afferent pupillary defect correlates with ischemia and serve to predict neovascular complications due to ischemic type of CRVO.

MANAGEMENT

- ▲ Panretinal laser photocoagulation (PRP) when rubeosis (= 2 clock hours of iris or any angle neovascularization), disc or retinal neovascularization, or neovascular glaucoma develops; NO BENEFIT TO PROPHYLACTIC PRP.
- ▲ Focal laser photocoagulation decreases macular edema but has no effect on visual acuity. No benefit in older patients with CRVO.
- ▲ Intravitreal 4mg triamcinolone acetonide (Kenalog) has been shown to decrease macular edema and transiently improve visual acuity.
- ▲ Discontinue oral contraceptives and change diuretics to an alternate antihypertensive.
- ▲ Consider aspirin 80 mg po qd.
- ▲ Treat underlying medical conditions.
- ▲ Unproven complex treatment includes antioxydants, rheologic drugs, and vasodilators.

FOLLOW-UP

Every 2-3 weeks for the first 6 months, watch for early signs of ischemia and neovascularization.

Clinical course is variable. Nonischemic has better prognosis. Two thirds of patients with ischemic disease develop neovascular complications; one third of nonischemic patients develop ischemic disease, especially older patients. ▼

8.3 BRANCH RETINAL VEIN OCCLUSION (BRVO)

Occlusion of a branch retinal vein (BRVO) usually caused by a thrombus at arteriovenous crossings where a thickened artery compresses the underlying venous wall (Fig. 8.5, 8.6).

ETIOLOGY

- Hypertension
- Coronary artery disease
- Diabetes mellitus
- Peripheral vascular disease.

Rarely associated with:

- Hypercoagulable, hyperviscosity states
- Systemic lupus erythematosus
- Syphilis
- Sarcoidosis
- Malignancies
- External compression

In younger patients associated with:

- Oral contraceptive pills
- Collagen-vascular disease
- AIDS
- Protein S / protein C / antithrombin III deficiency or activated protein C resistance

EPIDEMIOLOGY

Usually seen in elderly patients, 60-70 years old; associated with hypertension, cardiovascular disease, diabetes mellitus, increased body mass index, and open-angle glaucoma; slight male and hyperopic predilection.

Two types: nonischemic (64%) and ischemic. Second most common vascular disease after diabetic retinopathy. Risk of another BRVO in the same eye is 3% and in the fellow eye is 12%.

SYMPTOMS:

Sudden, unilateral, painless, visual field defect. Patients may have normal vision, especially when macula is not involved.

SIGNS:

- Quadrantic visual field defect

- Dilated, tortuous retinal veins with superficial retinal hemorrhages and cotton-wool spots in a wedge-shaped area radiating from an arteriovenous crossing (usually arterial overcrossing where an arteriole and venule share a common vascular sheath). More common superotemporally (60%) than inferotemporally (40%), rare nasally, since usually asymptomatic. The closer the obstruction is to the optic disc, the greater the area of retina involved and more serious the complications. Microaneurysms or macroaneurysms, macular edema (50%), epiretinal membranes, retinal and/or iris or angle neovascularization (very rare) and vitreous hemorrhage may develop. Neovascular glaucoma is rare.

DIFFERENTIAL DIAGNOSIS

Hypertensive retinopathy,
leucemic retinopathy,
retinopathy of anemia,
diabetic retinopathy,
papilledema,
papillophlebitis (in young patients).

WORK-UP

- Complete ophthalmic history and eye examination with attention to pupils, tonometry, gonioscopy, ophthalmoscopy.
- Check blood pressure
- Lab tests: fasting blood glucose, complete blood count, ESR, coagulability
- FAG, ICG
- Medical consultation for complete cardiovascular evaluation

MANAGEMENT

- ▲ Quadrantic scatter photocoagulation when rubeosis (= 2 clock hours of iris or any angle neovascularization), disc or retinal neovascularization, or neovascular glaucoma develops; PROPHYLACTIC LASER IS NOT RECOMMENDED.
- ▲ Macular grid / focal photocoagulation when macular edema lasts > 3 months and vision is more than 20/40 (Fig. 8.7).

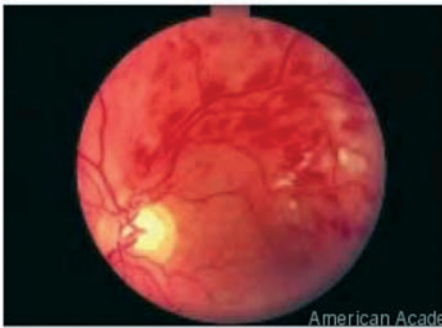

Fig. 8.5 Supertemporal branch retinal vein occlusion

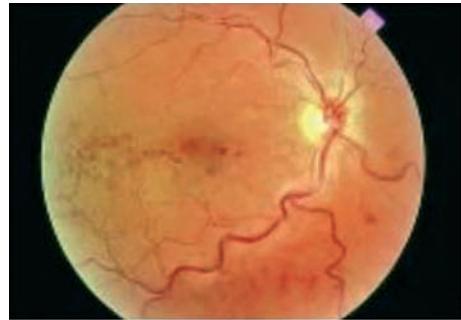


Fig. 8.6 Inferotemporal branch retinal vein occlusion

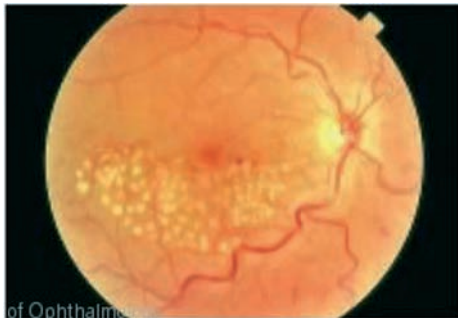

Fig. 8.7 Laser photocoagulation given in a full scatter grid using 100 mm spot size

- ▲ Intravitreal 4mg triamcinolone acetonide (Kenalog) for macular edema.
- ▲ Discontinue oral contraceptives and change diuretics to an alternate antihypertensive.
- ▲ Consider aspirin 80 mg po qd.
- ▲ Treat underlying medical conditions.
- ▲ Unproven complex treatment includes antioxydants, rheologic drugs, vasodilators

FOLLOW-UP

Every 1 month at first, then every 3 months, checking for neovascularization, macular edema or both.

PROGNOSIS

Good; 50% have = 20/40 vision unless foveal ischemia or chronic macular edema is present. ▼

9. MACULA DISORDERS

9.1 AGE-RELATED MACULAR DEGENERATION (AMD)

Progressive degenerative disease of the retinal pigment epithelium, Bruch's membrane and choriocapillaries.

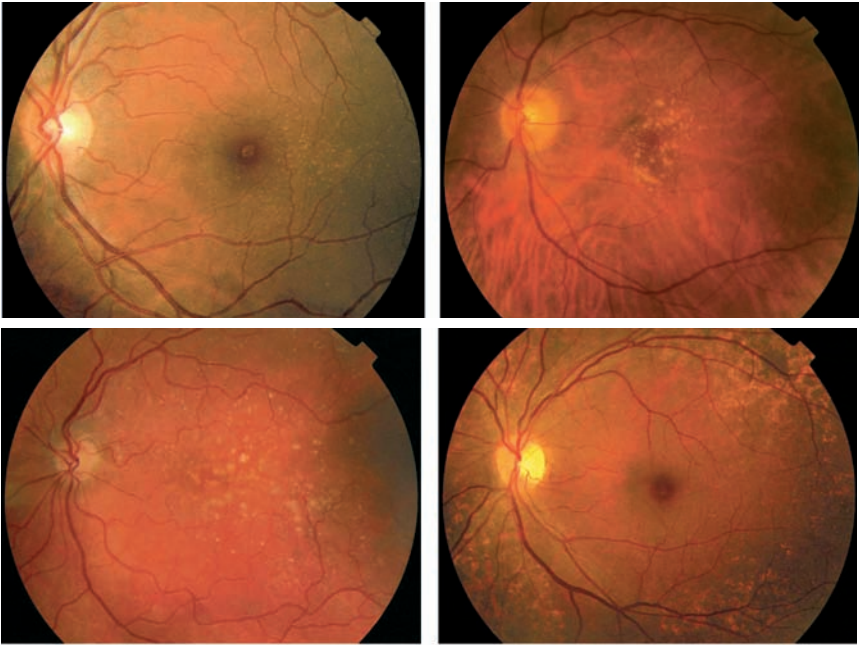
Generally classified into two types: (1) non-exudative or "dry" AMD (Fig. 9.1), characterized by drusen and pigmentary changes (90%) (Fig. 9.2), and (2) exudative or "wet" AMD, characterized by choroidal neovascularization (CNV) (Fig. 9.3) and eventually disciform scarring (10%) (Fig. 9.4).

EPIDEMIOLOGY:

The most common cause of blindness in the Western world, leading cause of blindness in US population in patients over 65 years of age. More prevalent in whites, slight female predilection.

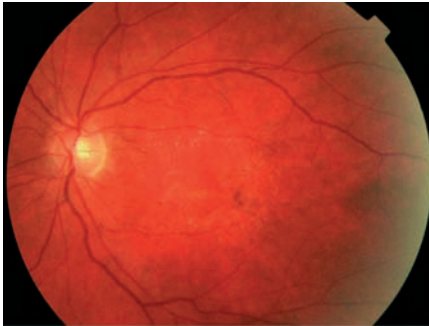RISK FACTORS:

- Age (over 75 years of age)
- Positive family history
- Cigarette smoking
- Hyperopia
- Light iris color
- Hypertension
- Hypercholesterolemia
- Female gender
- Cardiovascular disease
- Nutritional factors and light toxicity also play a role in pathogenesis. There may also be a genetic component to AMD.



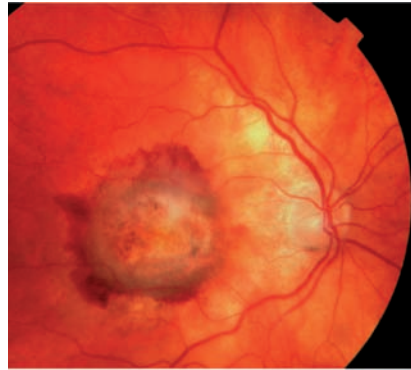
© 2005 Elsevier Ltd. Spalton et al: Atlas of Clinical Ophthalmology 3e

Fig. 9.1 Macular Drusen



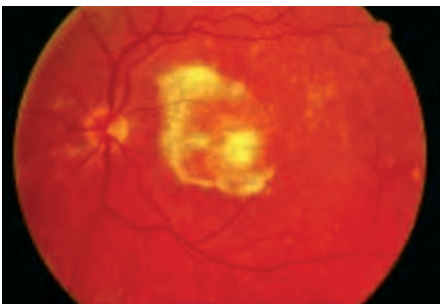
© 2005 Elsevier Ltd. Spalton et al: Atlas of Clinical Ophthalmology 3e

Fig. 9.2 Atrophic macular changes



© 2005 Elsevier Ltd. Spalton et al: Atlas of Clinical Ophthalmology 3e

Fig. 9.3 Grey-green choroidal neovascular membrane. Classic leakage



© 2005 Elsevier Ltd. Spalton et al: Atlas of Clinical Ophthalmology 3e

Fig. 9.4 Photograph of the endstage CNV that has progressed to fibrovascular scar

9.2 NONEXUDATIVE (DRY) MACULAR DEGENERATION

SYMPTOMS:

- Initially asymptomatic, or possibly decreased vision
- Metamorphopsia early
- Central or pericentral scotoma in advanced atrophic form

SIGNS:

- Normal or decreased visual acuity
- Abnormal Amsler grid (central/ paracentral scotoma or metamorphopsia)
- Small, hard drusen (Fig. 9.1)
- Larger, soft drusen
- Geographic atrophy of the retinal pigment epithelium (RPE) (Fig. 9.2)
- RPE clumping
- Blunted foveal reflex

DIFFERENTIAL DIAGNOSIS:

- Best's disease
- Stargardt's disease
- Drug toxicity

EVALUATION:

- ▲ Complete ophthalmic history and eye examination with attention to Amsler grid and 70/90 diopter or contact lens fundus examination.
- ▲ Fluorescein angiogram: Window defects from geographic atrophy and punctate hyperfluorescent staining of drusen (no late leakage).

MANAGEMENT:

- ▲ Follow with Amsler grid qd and examine every 6 months; examine immediately if patient has a change in vision, metamorphopsia or change in Amsler grid (significant progression of AMD to CNS- wet type).
- ▲ Supplement with high dose antioxidants and vitamins (vitamin C – 500

mg; vitamin E – 400 IU; beta carotin – 15 mg; zinc – 80 mg and copper – 2 mg) for patients with extensive intermediate-size drusen, one large, or non-central geographic atrophy, or with vision loss due to AMD in one eye.

WARNING:

Smokers should not take beta carotin at such high doses due to increased risk of lung cancer.

- ▲ Consider supplement with lower dose antioxidants (e.g. Centrum Silver, iCaps, Ocuville, Extra) for patients with few small drusen, extensive small drusen or few intermediate-size drusen, and patients with strong family history.
- ▲ Supplementation with other vitamins, including lutein and bilberry still unproved.
- ▲ Low vision aids may benefit patients with bilateral central visual loss due to geographic atrophy.

PROGNOSIS:

Usually good, unless patient develops central geographic atrophy or progresses to CNV wet type or exudative AMD. Severe vision loss (defined as loss of more than 6 lines of vision) occurs in 12% of nonexudative cases; presence of large soft drusen and focal RPE hyperpigmentation increases risk of developing exudative form. ▼

9.3 EXUDATIVE (WET) MACULAR DEGENERATION

SYMPTOMS:

Metamorphopsia
Central scotoma
Rapid visual loss

SIGNS:

- Grey-green choroidal neovascular membrane (CNV) (Fig. 9.3)
- Lipid exudates
- Subretinal or intraretinal hemorrhage or fluid

- Pigment epithelial detachment (PED)
- Retinal pigment epithelial tears
- Fibrovascular disciform scars (Fig. 9.4)

DIFFERENTIAL DIAGNOSIS:

Epiretinal membrane
 Macular hole
 Best's disease
 Central serous chorioretinopathy
 Stargardt's disease
 Drug toxicity
 Choroidal neovascularization from myopic degeneration
 Traumatic choroidal rupture

EVALUATION:

- ▲ Complete ophthalmic history and eye examination with attention to Amsler grid and 70/90 diopter or contact lens fundus examination.
- ▲ Fluorescein angiogram:
 - Leakage from CNV defined as two forms:
 - (1) Classic leakage (Fig. 9.3), defined as lacy network of bright fluorescence during early choroidal filling views, that increases in fluorescence throughout the angiogram and leaks beyond its borders in late views;
 - (2) Occult leakage (Fig. 9.5)

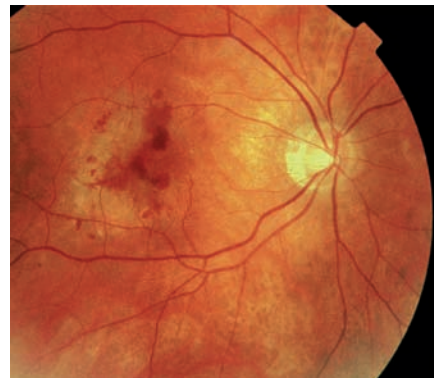

Fig. 9.5 Grey-green choroidal neovascular membrane. Occult leakage

- ▲ Indocyanine green angiogram: useful when the CNV is poorly demarcated or obscured by hemorrhage on fluorescein angiogram or if fibrovascular pigment epithelial detachment is present (to identify areas of neovascularization); CNV also appears as plaque of late hyperfluorescence.
- ▲ Optical coherence tomography: after photodynamic therapy (PDT), when the fluorescein angiogram is equivocal between leakage and staining of the CNV, OCT is useful to delineate the presence and extent of intraretinal and subretinal fluid, as well as the presence of a PED.

MANAGEMENT:

- ▲ Focal laser photocoagulation with argon green/ yellow or krypton red laser and a transpupillary delivery system to form confluent white burns over the entire CNV depending on size, location and visual acuity in patients with a classic, well-defined CNV.
- ▲ Although laser photocoagulation was shown to be beneficial, its use in subfoveal lesions has been supplanted by PDT. Photodynamic therapy with verteporfin (Visudyne) has been shown to prevent visual loss in subfoveal, predominantly classic lesions (over 50% of the entire lesion is composed of classic CNV). FAG must be performed within 7 days of PDT treatment to determine lesion size for treatment, PDT retreatment applied as often as every 3 months in fluorescein leakage found from CNV. Patient should avoid direct sunlight or bright indoor halogen lights for at least 48 hours after each treatment.
- ▲ There had been no effective treatment for minimally classic CNV; however the use of Triamcinolone/Avastin/Macugen/Lucentis intravitreal injections has been found to reduce progression of CNV and in the case of Lucentis, actually show improvement of vision. Treatment needs to be repeated frequently, often monthly. Costs of medications vary greatly.
- ▲ In certain select cases submacular surgery for removal of CNV or macular translocation performed by an experienced vitreoretinal surgeon may be considered (experimental).

- ▲ Low vision aids and registration with blind services for patients who are legally blind (<20/200 best corrected visual acuity or <20degree visual field in better seeing eye).
- ▲ Treatment being evaluated in clinical trials includes radiation therapy, transpupillary thermal therapy, modulating (feeder) vessel laser photocoagulation, different timing and doses of verteporfin PDT, and antiangiogenic or angiostatic agents with or without PDT.

PROGNOSIS

Usually poor prognosis; severe visual loss (defined as loss of more than 6 lines of vision) occurs in 88% of cases. Chance of severe visual loss is decreased with laser treatment (except in subfoveal group) and PDT. CNV may recur or persist after PDT or laser treatment; risk of fellow eye developing CNV is 4-12% annually. ▼

9.4 CENTRAL SEROUS CHORIORETINOPATHY

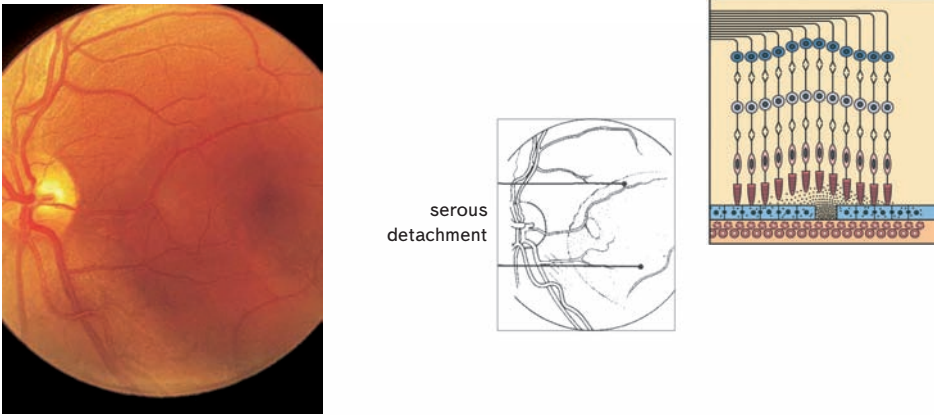
Central serous chorioretinopathy (CSC) is a condition characterized by serous elevation of the sensory retina in the macula, typically affecting young male patients (Fig. 9.6).

ETIOLOGY

Pathogenesis unknown; thought to be due to a localized abnormality in the RPE fluid pump.

SIGNS AND SYMPTOMS:

Blurred vision
 Metamorphopsia
 Micropsia
 Hyperopic shift in refraction (due to elevation of sensory retina)



© 2005 Elsevier Ltd. Spalton et al: Atlas of Clinical Ophthalmology 3e

Fig. 9.6 Central serous retinopathy

DEMOGRAPHICS

- Young to middle-aged adults
- Male to female ratio is 8:1 to 10:1
- "Type A" personality

OPHTHALMIC FINDINGS

- ▲ Serous retinal detachment in macula
- ▲ Subretinal yellowish precipitates
- ▲ Atrophic RPE changes (evidence of previous episodes) in ipsilateral or contralateral eye
- ▲ Extramacular RPE tracts

SYSTEMIC FINDINGS

None

SPECIAL TESTS

- ▲ **Fluorescein angiography:** classic "smokestack" with focal point of hyperfluorescence that rises, then diffuses laterally in 15% to 20% of cases. Majority have focal point of hyperfluorescence that increases slightly.
- ▲ **OCT**

DISEASE COURSE

- ▲ Spontaneous resolution of subretinal fluid occurs in 3-4 months with improvement of visual acuity to 20/30 or better in over 90% of patients.
- ▲ Recurrence may occur in up to 50% of patients..
- ▲ Uncommon complications include CNVM, macular edema, and peripheral chorioretinal atrophic tracts.

TREATMENT AND MANAGEMENT

- ▲ **Observation:** prescribing hyperopic glasses may help to temporize until CSC resolves.
- ▲ **Focal laser photocoagulation:** may hasten resolution of fluid. However, final visual acuity and recurrence rates are unaffected. Photocoagulation is usually reserved for patients in whom (1) occupational needs require hastened resolution, (2) prolonged leakage persists over 4-6 months, or (3) previous episode resulted in a permanent loss of vision.

MEDICATIONS

None effective

DIFFERENTIAL DIAGNOSIS

- ▲ Serous detachments in pregnancy, hypertension, or corticosteroid use.
- ▲ Age-related macular degeneration.
- ▲ **Rhegmatogenous retinal detachment:** look for peripheral retinal breaks. ▼

9.5 CYSTOID MACULAR EDEMA

Cystoid macular edema (CME) is the accumulation of fluid in a petalloid pattern in the outer plexiform layer of the macula (Fig. 9.7). It may be seen in many ocular diseases.

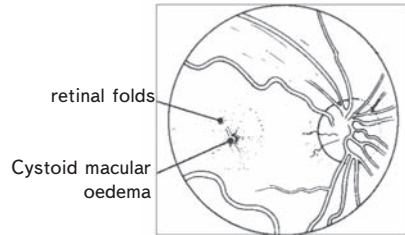
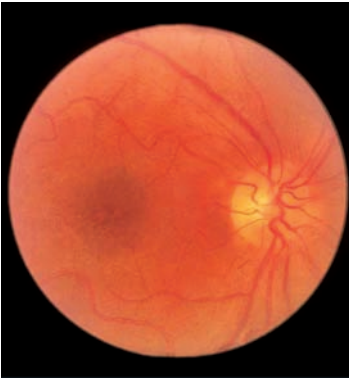

Fig. 9.7 Cystoid macular oedema

CAUSES OF CME

Postsurgical

- Cataract extraction, especially with INTRACAPSULAR CATARACT EXTRACTION
- Capsular rupture or vitreous loss.
- Vitrectomy.
- Cyclophotocoagulation
- Cryopexy
- Uveitis
- Vascular
- Vein occlusion (BRVO, CRVO)
- Diabetes mellitus
- Miscellaneous
- Retinitis pigmentosa
- Cytomegalovirus (CMV) retinitis
- PHOTOTOXICITY DUE TO LONG SURGERY UNDER SURGICAL MICROSCOPE

ETIOLOGY

- Mechanism of disease is unknown.

- Hypotheses include:
- Inflammation due to surgery, uveitis, or other factors
- Vitreous traction: leads to retinal capillary dilation and leakage.
- Ultraviolet light: may generate free radicals, leading to prostaglandin release.

SIGNS AND SYMPTOMS

- Unilateral decreased vision or metamorphopsia
- Dulled foveal reflex or foveal cysts noted on slit-lamp biomicroscopy

OPHTHALMIC FINDINGS

- Foveal cysts or dulled foveal reflex, usually unilateral
- IOL; possible PC tear or vitreous strands to wound or iris if associated with complicated cataract extraction
- IF ASSOCIATED WITH VASCULAR OPHTHALMOPATHY (DIABETIC ETINOPATHY OR CRVO) MAY HAVE microaneurysms, cotton-wool spots, OR perimacular edema OR HEMORRHAGES
- Anterior chamber cell and flare, vitreous cells, other signs of inflammation associated with uveitic causes.
- Pigmentary retinopathy, attenuated retinal vessels, waxy pallor of optic disk if associated with retinitis pigmentosa (RP).
- Distortion of intraretinal vessels, contraction of macular surface secondary to epiretinal fibrosis.

SYSTEMIC FINDINGS

- Depends on etiology
- Diabetic patients may have nephropathy, neuropathy, or other microvascular abnormalities.
- Patients with venous occlusive disease may have signs of systemic vascular disease, hypertension, hypercholesterolemia, etc.

SPECIAL TESTS

- ▲ Fluorescein angiographic characteristics (Fig. 9.8):
 - Focal areas of hyperfluorescence early.
- ▲ Late pooling of dye in cystoid spaces IN PETALOID APPEARANCE
 - OCT demonstrates elevation of the superficial retinal layers with accumulation of fluid within mid retina.

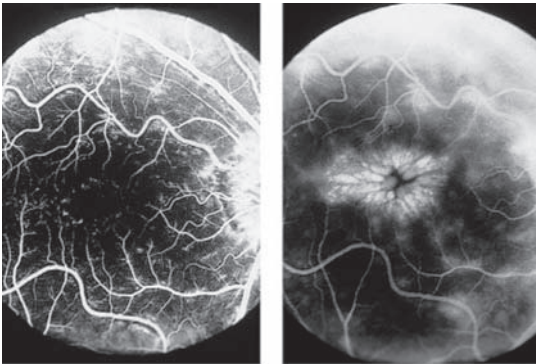


Fig. 9.8 Fluorescein angiography in cystoid macular oedema

© 2005 Elsevier Ltd. Spalton et al: Atlas of Clinical Ophthalmology 3e

DISEASE COURSE

Depends on etiology

- Acute APHAKIC OR pseudophakic CME may resolve over weeks to months without treatment.
- Chronic APHAKIC OR pseudophakic CME frequently persists, ultimately resulting in chronic photoreceptor and RPE alterations.
- CME associated with diabetic retinopathy gradually progresses and can result in significant visual decline.
- CME associated with uveitis waxes and wanes with the underlying uveitis.

TREATMENT AND MANAGEMENT

Depends on etiology

- APHAKIC or pseudophakic CME - most common cause
- Stepwise treatment options:
1. Topical nonsteroidal anti-inflammatory drugs (NSAIDs) and /or topical prednisolone for 1-3 months.
 2. Corticosteroids - subtenons (triamcinolone 40mg/1 ml) or intravitreal (triamcinolone 4 mg).

3. Nd:YAG laser vitreolysis or anterior segment reconstruction when indicated.
4. Pars plana vitrectomy
 - Diabetic macular edema; intravitreal Triamcinolone/Avastin/Macugen/Lucentis intravitreal injections or focal or grid laser for clinically significant edema.
 - BRVO: focal or grid laser for persistent macular edema and vision 20/40 or worse. Triamcinolone/Avastin/Macugen/Lucentis intravitreal injections are helpful here as well.
 - Uveitis: topical, periocular, and systemic corticosteroids; refractory cases may require immunosuppressives.

MEDICATIONS

- Topical NSAIDs (diclofenac) and steroids are most commonly used for initial treatment of pseudophakic CME. Treatment is instituted at four times a day for at least 1 to 2 mo, and then tapered slowly when vision stabilizes
- Systemic corticosteroids may be beneficial in the treatment of CME associated with uveitis.
- Acetazolamide has shown limited success in the treatment of CME associated with RP and CMV retinitis.

FOLLOW-UP

- Pseudophakic CME: monthly or every other month while on treatment.
- Eight weeks after laser treatment (diabetic and vein occlusion patients).

DIFFERENTIAL DIAGNOSIS

- Macular degeneration: Exudative disease can result in CME associated with drusen, subretinal and intraretinal hemorrhage
- Epiretinal membrane
- Macular hole
- Choriorretinal neovascularization
- Peripheral retinal break

POINTS TO REMEMBER

CME may be prevented by the use of nonsteroidal anti-inflammatory drugs (NSAID) prior to cataract surgery.▼

10 RETINAL DISEASES



10.1 RETINAL DETACHMENT (RD)

Separation of neurosensory retina from underlying RPE due to subretinal fluid.

ETIOLOGY

- Retinal tear with leakage of liquefied vitreous into subretinal space (Fig. 10.1).
- Traction due to PDR, ROP, PVR.
- Exudation of serous fluid from systemic disease, inflammation, tumor.

SIGNS AND SYMPTOMS

Flashes, floaters.

Loss of peripheral visual field.

Loss of central vision if macula involved. ▼

Fig.10.1 Horseshoe retinal tear with associated retinal detachment. Intact retinal vessel bridges tear

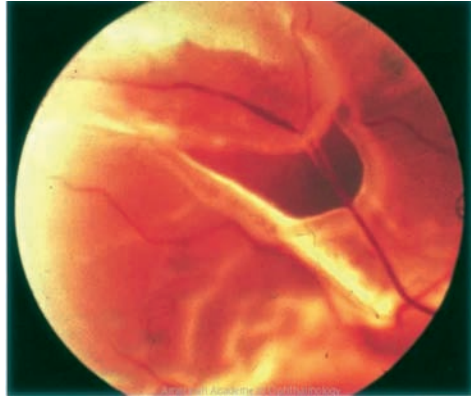
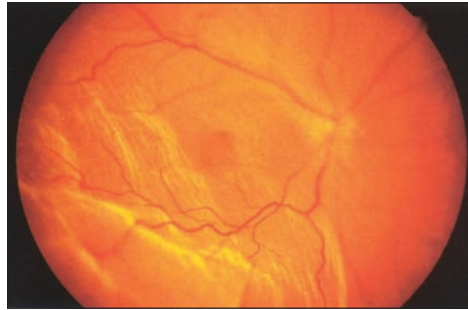


Fig.10.2 Primary retinal detachment



10.2 RHEGMATOGENOUS RETINAL DETACHMENT DUE TO RETINAL TEAR - PRIMARY RD (FIG. 10.2)

RISK FACTORS

- RD in fellow eye.
- Family history of RD.
- High-level myopia.
- Aphakia, pseudophakia with or without Nd:Yag laser posterior capsulotomy.
- Blunt trauma.
- Retinal necrosis (e.g., CMV retinitis).

SIGNS

- PVD, vitreous syneresis.
- Schaffer's sign, tobacco dust: pigment cells in vitreous.
- Subretinal fluid associated with identifiable retinal break in more than 90% of cases.
- Retinal folds.
- May have low IOP.

DISEASE COURSE

- Progression to total RD without treatment.
- If macula is attached on presentation, visual prognosis relatively good, but requires immediate referral.
If macula is detached, there is a lower rate of both anatomic success and visual recovery. Less than 40% recover vision of 20/50 or better. Prognosis worsens with time from macular involvement
- Proliferative vitreoretinopathy decrease rate of success of surgical repair.

TREATMENT AND MANAGEMENT

- Goal is to close the retinal break(s).
- Scleral buckling procedure (anatomic success achieved in more than 90%).
- Vitrectomy
- Pneumatic retinopexy.

FOLLOW-UP

Timing of surgical repair is important, since longstanding detachments have the worst visual prognosis.

10.3 SECONDARY DETACHMENTS - TRACTIONAL RD AND EXUDATIVE RD

TRACTIONAL RETINAL DETACHMENT DUE TO PRERETINAL FIBROSIS AND MECHANICAL CONTRACTION (Fig. 10.3)

Not necessarily associated with retinal breaks

DEMOGRAPHICS

PDR
ROP
Proliferative vitreoretinopathy
Penetrating trauma

SIGNS

- Preretinal fibrovascular proliferation/membranes.
- Concave retinal surface.
- Detachment is usually localized to the region of preretinal membranes.
- Subretinal fibrosis.

SYSTEMIC FINDINGS

- Diabetes mellitus
- Prematurity.
- Other proliferative vascular disease like CRVO, Eales disease

TREATMENT AND MANAGEMENT

Vitrectomy with membrane dissection.

EXUDATIVE RETINAL DETACHMENT: SEROUS SUBRETINAL FLUID NOT DUE TO PRIMARY RETINAL BREAK OR VITREOUS TRACTION (Fig 10.4)

ETIOLOGY AND RISK FACTORS

- Inflammatory disease: posterior scleritis, sympathetic ophthalmia.
- Neoplasm: choroidal malignant melanoma, choroidal metastasis.
- Systemic disease such as malignant hypertension, renal failure, toxemia of pregnancy.
- Exudative ARMD

SIGNS

- Bullous, shifting subretinal fluid.
- NO PRIMARY RETINAL BREAK FOUND.
- NO pigmented vitreous cells.
- May have underlying tumor: melanoma, retinoblastoma.

SPECIAL TESTS

- FAG: Melanoma may show increased vascularity of the lesion, ARMD may demonstrate choroidal neovascularization.
- B-scan.

TREATMENT AND MANAGEMENT

- Treat underlying systemic condition, co-manage with an internist.
- Drainage of subretinal fluid may be achieved by sclerotomies.

MEDICATIONS

Consider corticosteroids in patients with chronic inflammatory disease, in those who develop serous RD following cryopexy or laser photocoagulation. ▼

Fig. 10.3 Retinal detachment with proliferative vitreoretinopathy

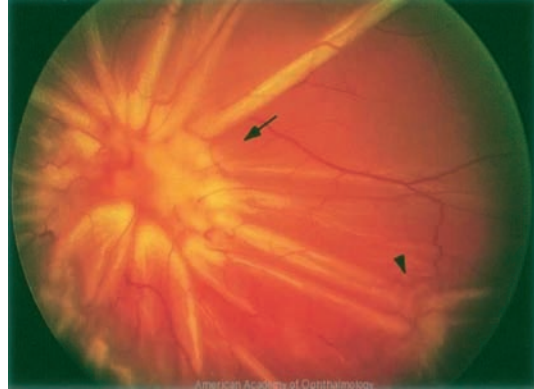
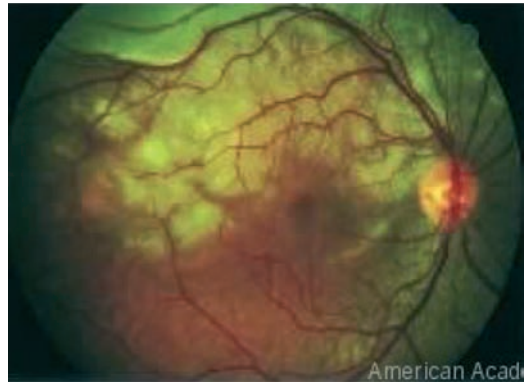

Fig. 10.4 Exudate retinal detachment as a result of posterior scleritis



11. OCULAR MANIFESTATIONS OF SYSTEMIC DISEASES

11.1 DIABETIC RETINOPATHY (DR)

Retinal vascular complication of diabetes mellitus classified into nonproliferative (NPDR) and proliferative (PDR) forms.

ETIOLOGY (THEORIES)

- ▲ Glycosylation of tissue proteins causes cell damage.
- ▲ Aldose reductase results in an accumulation of intracellular sorbitol which causes basement membrane thickening and damages pericytes.
- ▲ The latest one: hyperglycemia can cause overactivation of protein kinase C β (PKC β), PKC β is now recognized as a key factor in the underlying process of microvascular damage that leads to diabetic retinopathy and diabetic macular edema.

Insulin-Dependent Diabetes (IDDM; type I)

Juvenile onset, usually occurs before 30 years of age. Most patients are free of retinopathy during first 5 years after diagnosis. Severity of DR worsens with increasing duration of diabetes mellitus.

Non-Insulin-Dependent Diabetes (NIDDM; type II)

Adult onset, usually diagnosed after 30 years of age. More common form (90%) with optimal control without insulin. Risk of DR increases with hypertension, chronic hyperglycemia, renal disease, hyperlipidemia

and pregnancy. Early treatment prevents the appearance of Proliferative Diabetic Retinopathy with Clinically Significant Macular Edema

SIGNS AND SYMPTOMS:

Blurring, distortion of vision
 Decreased night vision
 Floaters
 Decreased color vision

DEMOGRAPHICS:

- Leading cause of blindness in patients aged 20 to 64.
- 25% of diabetic patients have diabetic retinopathy.

OPHTHALMIC FINDINGS IN NONPROLIFERATIVE DIABETIC RETINOPATHY (FIG 11.1-11.4):

- ▲ Microaneurysms
- ▲ Dilated capillaries
- ▲ Dot-blot nerve-fiber layer hemorrhages
- ▲ Hard exudates
- ▲ Retinal edema
- ▲ Cotton-wool spots

SYSTEMIC FINDINGS:

Diabetic nephropathy

Polyneuropathy

Hypertension found in 22% of the type I and 58% of the type II diabetic patients

NONPROLIFERATIVE DIABETIC RETINOPATHY (NPDR)

- ▲ **Mild:** occasional microaneurysms
- ▲ **Moderate:** more microaneurysms and scattered hard exudates or cotton-wool spots
- ▲ **Severe:** the presence of one of the following:

- ▲ Diffuse intraretinal hemorrhages and microaneurysms in 4 quadrants,
or
Venous beading in 2 quadrants, or
Intraretinal microvascular abnormalities (IRMA) in 1 quadrant.

Clinically Significant macular Edema (CSME)

Retinal thickening = 500 μm from center of fovea, or

Hard exudates = 500 μm from center of fovea with adjacent thickening, or

Retinal thickening = 1 disk area in size at 1 disk diameter from center of fovea.

PROLIFERATIVE DIABETIC RETINOPATHY (PDR)

The presence of newly formed blood vessels (Fig. 11.5) or fibrous tissue arising from the retina or optic disc and extending along the inner surface of the retina or disc into vitreous cavity.

ETIOLOGY

Closure of retinal arterioles causes nonperfusion and ischemia and stimulates the release of vasoproliferative factors stimulating neovascularization from the retina, optic nerve or iris.

SIGNS AND SYMPTOMS:

- ▲ Blurred vision
- ▲ Distortion
- ▲ Floaters

DEMOGRAPHICS:

- 26% of patients who have had diabetes for 25 to 50 years develop PDR.
- Type I diabetic patients have a higher risk of developing PDR than type II patients.

OPHTHALMIC FINDINGS:

Neovascularization of the disc (NVD) or elsewhere (NVE)
Vitreous or preretinal hemorrhages
Preretinal fibrosis
Tractional retinal detachment (TRD)

High-risk (HR) characteristics of PDR

Neovascularization of the disc (NVD) = one quarter to one third disk area, or
Any NVD and vitreous hemorrhage or preretinal hemorrhage, or
Neovascularization elsewhere (NVE) = one half disk area and vitreous hemorrhage or preretinal hemorrhage.

SYSTEMIC FINDINGS:

Nephropathy
Polyneuropathy
Hypertension
Carotid occlusive disease

Main cause of vision loss in NPDR:

Macular edema or ischemia

Main causes of vision loss in PDR:

Tractional retinal detachment
Vitreous hemorrhage
Neovascular glaucoma (NVG)

OTHER SEQUELAE:

1. Fluctuation in refractive error due to osmotic effect on crystalline lens from unstable blood sugar levels
2. Diabetic cataract
3. Isolated cranial nerve palsies: CN 3, 4, 6
4. Papillitis: acute disk swelling
Consider diabetes mellitus in patient requiring frequent changes of glasses: increased myopia correlates with elevated blood sugar.

WORK-UP

- ▲ Complete ophthalmic history and eye examination with attention to tonometry, gonioscopy (NVG), iris (NVI), lens ophthalmoscopy, 90 diopter lens fundus examination (retinal vascular abnormalities, optic disc (NVD) and midperiphery (NVE), and indirect ophthalmoscopic view of periphery
- ▲ IDDM (type I): examine 5 years after onset of diabetes, then annually if no retinopathy is seen.
- ▲ NIDDM (type I): examine at diagnosis of diabetes, then annually if no retinopathy is seen.
- ▲ During pregnancy: examine before pregnancy, each trimester and 3-6 months postpartum.

LAB TESTS:

Fasting blood glucose
Hemoglobin A1C (serum glycosylated hemoglobin)
Blood urea nitrogen and creatinine

FAG, ICG:

Capillary nonperfusion, microaneurysms, macular edema and disc or retinal neovascularization

OCT:

Increased retinal thickness, cysts and subretinal fluid in case of macular edema; can highlight the presence of posterior hyaloid traction and traction macular detachment.

SCAN ULTRASONOGRAPHY:

Used to rule out tractional retinal detachment in eyes when dense vitreous hemorrhage obscures view of fundus or significant cataract obscures view of fundus. Cataract extraction may become necessary to follow patient and deliver laser treatment.

Medical consultation with attention to blood pressure, cardiovascular disease, renal status and glycemic control.

MANAGEMENT:

- ▲ Tight control of blood sugar slows progression of retinopathy, diabetic macular edema in patients with type I and type II diabetes.

POINTS TO REMEMBER:

Rapid normalization and tight control of blood sugar after a period of prolonged hyperglycemia can lead to worsening of retinopathy.

- ▲ Laser photocoagulation using transpupillary delivery and argon green (focal/ panretinal photocoagulation) or krypton red laser (panretinal photocoagulation when vitreous hemorrhage or cataract is present), depending on stage of diabetic retinopathy (Fig. 11.6).
- ▲ **Clinically Significant macular Edema (CSME):** macular grid photocoagulation to areas of diffuse leakage and focal treatment to focal leaks regardless of visual acuity.
- ▲ High-risk PDR: scatter panretinal photocoagulation (PRP) 1200-1600 burns, in two or three sessions. Treat inferior and nasal quadrants first to allow further treatment in case of subsequent vitreous hemorrhage during treatment and to avoid worsening macular edema.
- ▲ Additional indications for panretinal photocoagulation: rubeosis, neovascular glaucoma, widespread retinal ischemia on fluorescein angiogram, NVE alone in IDDM, poor patient compliance, and severe NPDR in the fellow eye or patient with poor outcome in the first eye.
- ▲ Pars plana vitrectomy, endolaser, and removal of any fibrovascular complexes in patients with nonclearing vitreous hemorrhage for 6 months, or vitreous hemorrhage for over 1 month in IDDM.
Other indications for vitreoretinal surgery include:
 - monocular patient with vitreous hemorrhage

- bilateral vitreous hemorrhage
- diabetic macular edema due to posterior hyaloidal traction
- tractional retinal detachment (TRD) with rhegmatogenous component
- TRD involving macula
- progressive fibrovascular proliferation despite complete PRP
- dense premacular hemorrhage or if ocular media are not clear enough for adequate view of fundus to perform PRP.

Should be performed by a retina specialist.

- ▲ Experimental pharmaceutical treatments for refractory, diffuse macular edema include posterior sub-Tenon's injection of 40 mg triamcinolone acetonide, intravitreal 4 mg triamcinolone acetonide, Bausch and Lomb's Retisert sustained-release (1000 day) implant with fluocinolone acetonide, Occulex biodegradable dexamethasone implant, proteinkinase C- β inhibitors and intravitreal antivascular endothelial growth factors (VEGF) injections
- ▲ Experimental surgical treatment for refractory, diffuse macular edema includes pars plana vitrectomy with peeling of posterior hyaloid with or without removal of the internal limiting membrane especially with the presence of a taut posterior hyaloid exerting traction on the macula.

PROGNOSIS:

Early treatment allows better control. Prognosis is good for NPDR without CSME. After adequate treatment diabetic retinopathy often becomes quiescent for extended periods. Focal laser photocoagulation improves vision in 17% of cases. Complications include cataract (often posterior subcapsular), and neovascular glaucoma. ▼

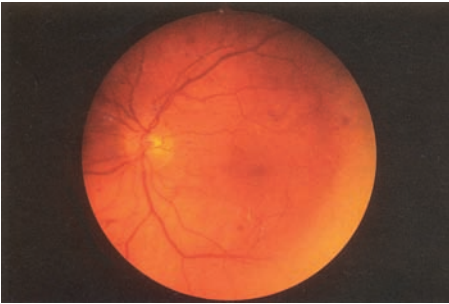

Fig.11.1 Nonproliferative diabetic retinopathy. Dot-and-blot hemorrhages and exudates are shown scattered throughout the posterior pole. Microaneurysms (pin-point dots) are difficult to see without high magnification

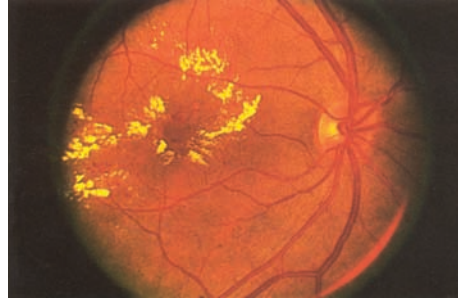


Fig.11.2 Exudates in nonproliferative diabetic retinopathy. Clusters of hard, yellowish exudates are prominent in the superior aspect of the macula. The exudates extend to the fovea, threatening the central vision.

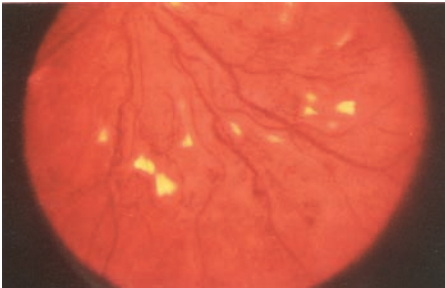


Fig.11.3 Cotton-wool spots in nonproliferative diabetic retinopathy. Microinfarctions of the nerve fiber layer produce the lesions shown. Cotton wool spots are opaque and white, have feathery edges, and obscure the underlying blood vessels. Venous beading and telangiectasia of the retinal vasculature are shown.

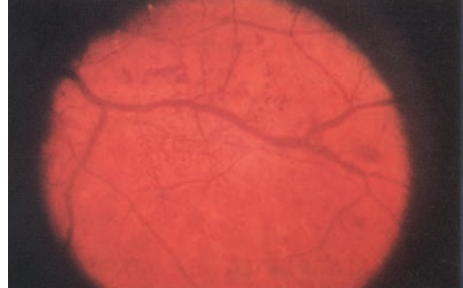


Fig.11.4 Preproliferative diabetic retinopathy. Venous beading, intraretinal microvascular abnormalities, and dot and blot hemorrhages are shown.

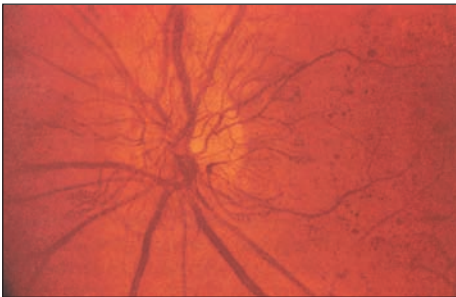


Fig.11.5 Proliferative diabetic retinopathy. Shown here is more advanced neovascularization of the optic nerve. These new vessels proliferate and extend into the vitreous.

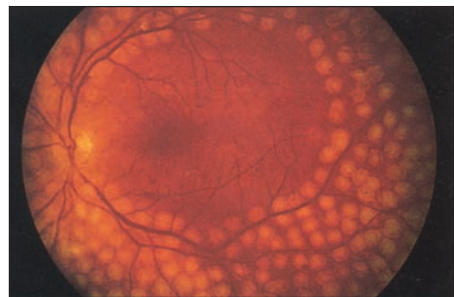


Fig.11.6 Panretinal argon laser photocoagulation. Shown here are old argon laser burns in the posterior pole of a diabetic patient with proliferative retinopathy. Initially the burns are white, but with time they develop variable pigmentation from chorioretinal scanning.

11.2 HYPERTENSIVE RETINOPATHY

A retinal vasculopathy due to systemic hypertension that can be acute or chronic.

PRESENTATION:

Chronic: patients are usually asymptomatic and have chronic essential hypertension (blood pressure: systolic over 140 mm Hg and/or diastolic over 90 mm Hg).

SIGNS AND SYMPTOMS:

- Retinal arteriolar sclerosis and narrowing (copper or silver wiring) (Fig. 11.7)
 - AV crossing and increased tortuosity (Fig. 11.8)
- Long-term complications include venous and arterial occlusions and macroaneurysms.

Acute: patients are more likely to be younger and to have a secondary cause of hypertension (preeclampsia, pheochromocytoma, hyperthyroidism, renal vascular or parenchymal disease, adrenal disease, Cushing's syndrome, alcohol withdrawal, or coarctation of the aorta).

SIGNS AND SYMPTOMS:

- Blurred vision
- Headache

There may be:

- Mental status change
- Chest pain
- Renal failure

OCULAR FINDINGS:

- Cotton-wool spots
- Hard exudates
- Flame-shaped retinal hemorrhages

Sclerotic changes may be absent.

- Choroidal ischemia causes pale patches of the retina (Elsching's spots, serous detachments, and retinal edema).
- Optic neuropathy with bilateral disc edema, congested veins and exudates in a macular star.

DIFFERENTIAL DIAGNOSIS:

- Diabetic retinopathy
- Collagen vascular disease
- Anemia
- Radiation retinopathy
- CRVO or BRVO
- Ischemic optic neuropathy

Macular star may be seen in hypertension, acute febrile illnesses, Behçet's disease, chronic infection such as TB or syphilis, papilledema due to increased intracranial pressure, papillitis and ocular trauma.

MANAGEMENT:

If the patient is asymptomatic and the blood pressure is moderately elevated referral to an internist is appropriate.

If the patient has symptoms of end-organ damage, including headache, chest pain, difficulty breathing, confusion or blurred vision with optic disc swelling and retinal hemorrhages, the patient requires immediate medical attention.▼

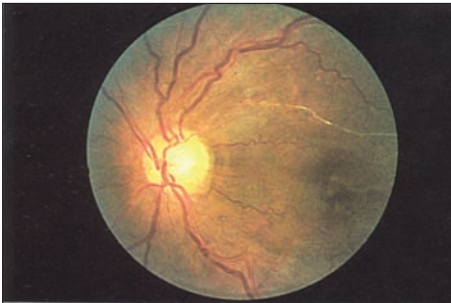


Fig.11.7 Hypertensive retinopathy. A single retinal vessel with areas of copper-wiring and silver-wiring is visible in this patient with long-standing hypertension.

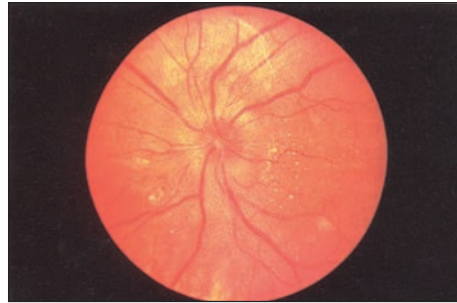


Fig.11.8 Arteriovenous crossing changes. In this magnified view, an abrupt right-angle change of a vein is visible at the first AV crossing, and nicking of the vein is seen at the second AV crossing.

12. GLAUCOMA

12. 1 PRIMARY OPEN-ANGLE GLAUCOMA

Progressive, bilateral optic neuropathy with open angles, typical pattern of nerve fiber bundle visual field loss, and increased intraocular pressure (IOP > 21 mm Hg) not caused by another systemic or local disease.

EPIDEMIOLOGY:

Occurs in 2% of general population and increases to 10% over 40 years of age.

Risk increases with age

60-70% of all forms of glaucoma

No sex predilection

RISK FACTORS:

- Increased IOP
- Increased cup:disc ratio (Fig. 12.1, 12.2)
- Thinner central corneal thickness (less than ~550 μ m by ultrasound or ~520 μ m by optical pachimetry)
- Black race
- Increased age
- Positive family history in first-degree relatives

Inconsistently associated factors:

Myopia

Diabetes mellitus

Hypertension

Cardiovascular disease
Gene mutation accounts for ~17% of POAG.

MECHANISMS

Elevated intraocular pressure:

- Mechanical resistance to outflow
- Disturbance of trabecular meshwork collagen
- Trabecular meshwork endothelial cell dysfunction, basement membrane thickening, glycosaminoglycan deposition, narrowed intertrabecular spaces, collapse of Schlemm's canal. A subgroup of patients have been identified with mutation of the myocilin glycoprotein. This protein is also mutated in patients with autosomal dominant juvenile open-angle glaucoma.

Vascular:

Poor optic nerve perfusion or disturbed blood flow autoregulation. Other pathways leading to apoptosis, a programmed ganglion cell death.

Excitotoxicity (glutamate), autoimmunity, abnormal glial-neuronal interactions, defects in endogenous protective mechanisms (heat shock proteins).

SYMPTOMS:

Asymptomatic

May have decreased vision or constricted vision fields in late stages.

SIGNS:

- Normal or decreased visual acuity
- Increased IOP
- Cupping of optic nerve
- Retinal nerve fiber layer defects
- Visual field defects

DIFFERENTIAL DIAGNOSIS:

Secondary glaucoma, normal tension glaucoma, ocular hypertension, optic neuropathy, physiologic cupping

WORK-UP

- ▲ Complete ophthalmic history and eye examination with attention to cornea, tonometry, anterior chamber, gonioscopy, iris, lens and ophthalmoscopy.
- ▲ Check corneal pachymetry (IOP measurement may be artificially high or low for thicker or thinner than average corneas, respectively).
- ▲ Check visual fields: visual field defects characteristic of glaucoma include: paracentral scotomas (within central 10° of fixation), arcuate (Bjerrum) scotomas (isolated, nasal step, or connected to blind spot), and temporal wedge
- ▲ Stereoptic nerve photos are useful for comparison at subsequent evaluations.
- ▲ **Optic nerve head analysis:**
Various methods, including optical coherence tomography (OCT), confocal scanning laser ophthalmoscopy, scanning laser polarimetry.

MANAGEMENT:

Because multiple factors may be involved in the etiology of glaucoma, neuroprotection has been proposed as a therapeutic strategy for glaucoma management.

At present, however, only therapy that reduces IOP has been proved to prevent future optic disk damage and progressive glaucomatous visual field loss.

POINTS TO REMEMBER:

Reduction of IOP remains the primary goal of glaucoma treatment. Substantial reduction of IOP is desirable, because every 1 mm Hg of additional IOP lowering may reduce the risk of disease progression.

In current practice a target IOP is often established as a goal of glaucoma therapy.

Target pressures should be set progressively lower as the disease advances and the risk of blindness increases.

The first line of therapy for most adult patients with open-angle glaucoma is medication.

MEDICAL TREATMENT:

Topical prostaglandine analogues have become first-line drugs. Monotherapy is preferable, but if intraocular pressure is not controlled, additional medications can be added. Follow-up (after intraocular pressure stabilization) at 3-4 weeks after changing treatment to evaluate efficacy. Treatment options include single doses or combinations of the following medications:

- ▲ Topical b-blockers (Timolol maleate [Timoptic], Betaxolol hydrochloride [Betoptic S], selective b1-blocker, Carteolol hydrochloride [Ocupress]) bid; decrease aqueous production; check for history of cardiac and pulmonary disease before prescribing.
- ▲ Topical a-adrenergic agonist (Brimonidine tartrate [Alphagan-P] tid); decreases aqueous production.
- ▲ Topical carbonic anhydrase inhibitor (Dorsolamide hydrochloride [Trusopt], Brinzolamide [Azopt]) tid; decreases aqueous production. Contraindicated in sulfur drug allergy.
- ▲ Topical cholinergic medication (Pilocarpine, qid); increases outflow through trabecular meshwork.
- ▲ Systemic carbonic anhydrase inhibitor (Acenazolumide [Diamox] qd to qid); decrease aqueous production; rarely used due to systemic side effects.

Laser and incisional surgical procedures for glaucoma are usually used only for:

1. Patients with IOP uncontrolled on maximum tolerated medical therapy.
2. Patients who are unable to comply with medical treatment.
3. The small percentage of patients who prefer surgery to medications.

These procedures usually do not provide permanent IOP control. Patients treated surgically often undergo additional procedures and frequently need to use medications to maintain IOP control.

Laser Treatment: trabeculoplasty, cyclophotocoagulation

- ▲ Argon laser trabeculoplasty (ALT) – spots are placed on the pigmented trabecular meshwork.
- ▲ Selective laser trabeculoplasty (SLT) - spots are placed to straddle the trabecular meshwork.
- ▲ Cyclophotocoagulation – diode laser cyclophotocoagulation is used to lower IOP in end-stage or refractory glaucoma. A specialized probe is used to destroy part of the ciliary body thereby reducing aqueous production.

SURGICAL TREATMENT:

- ▲ Trabeculectomy – the traditional surgical procedure.
- ▲ Nonpenetrating deep sclerectomy is associated with fewer complications than trabeculectomy, but it may have a lower success rate in reducing IOP.
- ▲ Glaucoma drainage implant – when there is inflammation or excessive scarring from previous glaucoma surgeries, an aqueous drainage device (Ahmed glaucoma valve implant or a Baerveldt glaucoma implant) may

be implanted to allow aqueous humor to drain through a tube from the interior of the eye to a reservoir outside the eye where humor is absorbed by blood vessels (Fig. 12.3).

PROGNOSIS

Usually good if intraocular pressure is controlled adequately.▼

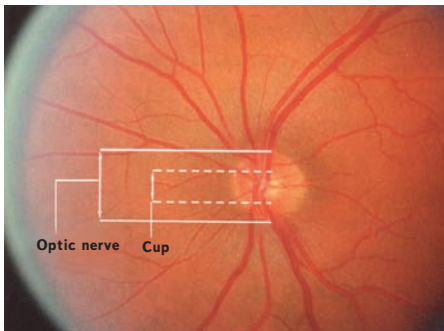


Fig.12.1 Cup:disc ratio. In this non disc, the cup is less than one half the diameter of the disc, indicating absent or low level of suspicion of glaucoma.

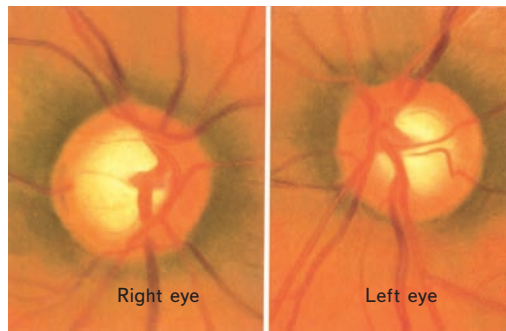

Fig.12.2 Glaucomatous cupping. The left side shows a cup:disc ratio of 0.9 (high level of glaucoma suspicion) and the right side shows a cup:disc ratio of 0.7 (moderate level of glaucoma suspicion). The asymmetry of the cup: disc ratios here also raises suspicion of glaucoma.

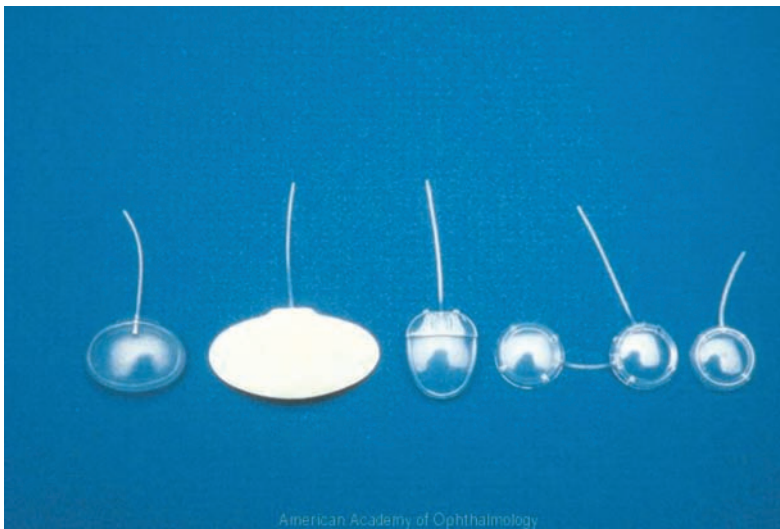


Fig.12.3 Glaucoma drainage devices; from left to right: Frופן, Baerveldt, Ahmed, double –plate Molteno, single-plate Molteno

12.2 NORMAL (LOW) TENSION GLAUCOMA

Similar optic nerve and visual field damage as in POAG, but with normal intraocular pressure (< 21 mm Hg).

EPIDEMIOLOGY

Higher prevalence of vasospastic disorders including migraine, ischemic vascular disease, autoimmune disease, and coagulopathies; also associated with history of poor perfusion of the optic nerve from hypotension, shock, myocardial infarction or massive hemorrhage.

SYMPTOMS:

Asymptomatic

May have decreased vision or constricted visual fields in late stages.

SIGNS:

- Normal or decreased visual acuity
- Normal IOP (< 21 mm Hg)
- Cupping of the optic nerve
- Splinter hemorrhages at the optic disc (more common than in POAG)
- Peripapillary atrophy
- Nerve fiber layer defects
- Visual field defects-

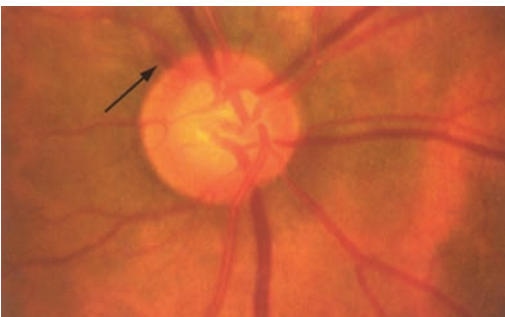

Fig.12.4 Splinter hemorrhages on the optic disc

DIFFERENTIAL DIAGNOSIS:

- ▲ POAG (undetected increased IOP or artificially low IOP secondary to thin cornea (e.g. naturally occurring or after LASIK or PRK))
- ▲ Secondary glaucoma (steroid-induced, "burned out" pigmentary or post-inflammatory glaucoma)
- ▲ Intermittent angle-closure glaucoma
- ▲ Optic neuropathy
- ▲ Optic nerve anomalies

WORK-UP

- ▲ Complete ophthalmic history and eye examination with attention to cornea, tonometry, anterior chamber, gonioscopy, iris, lens and ophthalmoscopy
- ▲ Check visual fields
- ▲ Check corneal pachymetry
- ▲ Consider diurnal curve (IOP measurement q 2h for 10-24 hours)
- ▲ Consider evaluation for other causes of optic neuropathy; check color vision, lab tests (CBC, ESR), neuroimaging, or cardiovascular evaluation if age less than 60 years old, decreased visual acuity without apparent cause, visual field defect not typical of glaucoma, visual field and disc changes do not correlate, rapidly progressive, unilateral or markedly asymmetric, or nerve pallor greater than cupping.

MANAGEMENT

- ▲ Choice and order of topical glaucoma medications depend on many factors, including patient's age, IOP level and control, amount and progression of optic nerve cupping and visual field defects. Treatment options are presented in the Primary Open-Angle Glaucoma section.

- ▲ Follow patients every 6 months with complete eye examination and visual fields. No treatment if stable unless other risk factors are present for progression (disc hemorrhage, history of migraine, or female); treatment goal is IOP reduction of 30% from baseline.

PROGNOSIS

Worse than for POAG ▼

12. 3 PRIMARY ANGLE-CLOSURE GLAUCOMA

Glaucoma due to obstruction of trabecular meshwork by peripheral iris; classified as acute, subacute (intermittent) and chronic.

ETIOLOGY/ MECHANISM

Pupillary block (most common): lens-iris apposition interferes with aqueous flow and causes iris to bow forward and occlude the trabecular meshwork (Fig. 12.5).

Plateau iris syndrome (without pupillary block): peripheral iris occludes angle in patients with atypical iris configuration (anteriorly positioned peripheral iris will steep insertion due to anteriorly rotated ciliary processes).

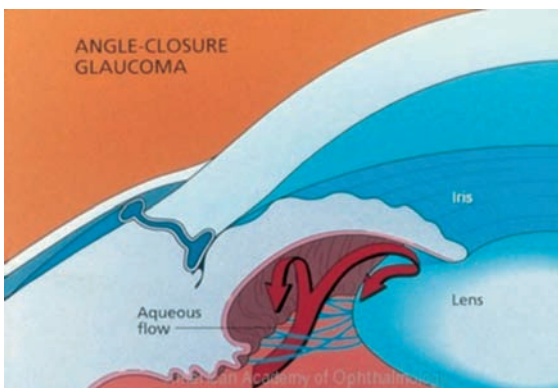


Fig.12.5 Schematic of angle-closure glaucoma with pupillary block leading to peripheral iris obstruction of the trabecular meshwork

EPIDEMIOLOGY

Female predilection (4:1); higher incidence in Asians and Eskimos; approximately 5% of the general population over 60 years old have occludable angles, 0,5% of these develop angle-closure; usually bilateral (develops in 50% of untreated fellow eye within 5 years); associated with:

- hyperopia
- nanophthalmos
- anterior chamber depth less than 2,5 mm
- thicker lens
- lens subluxation

SYMPTOMS:

Acute angle-closure:

1. Colored halos around lights to differentiate from patients with cataract
2. Red eye
3. Photophobia
4. Blurred vision
5. Headache or brow ache becomes severe
6. Nausea, vomiting

Subacute angle-closure:

- **mild headache and blurred vision in the morning or photophobia upon awaking;**
may be asymptomatic or have symptoms of acute form but less severe;
episodes evolve over the course of days or weeks and resolve spontaneously.

Chronic angle-closure:

Asymptomatic; may have decreased vision or constricted visual fields in late stages.

SIGNS::

Acute angle-closure (Fig. 12.6):

- Decreased visual acuity
- Increased intraocular pressure
- Ciliary injection

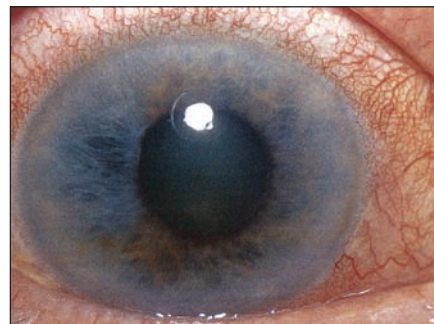


Fig.12.6 Acute angle-closure glaucoma

- Corneal edema
- Anterior chamber cells and flare
- Shallow anterior chamber
- Narrow angles on gonioscopy
- Mid-dilated, nonreactive pupil, iris bombe
- May have signs of previous attacks including sector iris atrophy, anterior subcapsular lens opacities, dilated irregular pupil and peripheral anterior synechiae.

Subacute and chronic angle-closure:

- Narrow angles
- May have increased IOP, peripheral anterior synechiae, anterior subcapsular lens opacities, visual field defects and optic nerve cupping.

WORK-UP

- ▲ Complete ophthalmic history and eye examination with attention to pupils, cornea, tonometry, anterior chamber, iris, indentation gonioscopy, lens and ophthalmoscopy.
- ▲ Check visual fields

MANAGEMENT**ACUTE ANGLE-CLOSURE: OPHTHALMIC EMERGENCY**

- ▲ Topical b-blocker (Timolol [Timoptic] 0,5% q. 15 minutes x2, then bid)
α-agonist (Apraclonidine [Iopidine] 1% q. 15 minutes x2), and topical steroid (Prednisolone acetate 1% q. 15 minutes x4, then q. 1h)
Topical miotic (Pilocarpine 1-2% q. 15 minutes x3)
- ▲ Usually not effective if intraocular pressure is >40 mm Hg due to iris sphincter ischemia.

POINTS TO REMEMBER

- ▲ Pilocarpine will be instilled no more than 3 times, since frequent instillation will exacerbate the situation due to forward displacement of the lens-iris diaphragm.

- ▲ Systemic acetazolamide in case the patient does not have allergy on sulfa drugs.
- ▲ Diamox 500 mg po, then bid.
- ▲ Hyperosmotic glycerol 50% po. put in glass with ice and juice. Makes it easier to tolerate
- ▲ **Laser peripheral iridotomy with or without iridoplasty.** This can be done immediately without waiting for attack to be broken medically. Usually requires application of topical glycerin (Ophthalgan) to clear corneal edema for adequate visualization for laser. Put in topical anesthetic first, since glycerine is painful.
- ▲ Prophylactic laser peripheral iridotomy in fellow eye with narrow angle to prevent an acute attack in the future.
- ▲ If unable to perform laser peripheral iridotomy, consider surgical iridectomy.
- ▲ Plateau iris syndrome may require long-term miotic therapy and peripheral iridectomy to reduce the risk of pupillary block; consider argon laser, iridoplasty or gonioscopy.
Cataract extraction or clear lensectomy may be necessary if narrow angle glaucoma is uncontrolled.

SUBACUTE AND CHRONIC ANGLE-CLOSURE

- ▲ Laser peripheral iridotomy even without evidence of pupillary block.
- ▲ Treatment of increased IOP; may require trabeculectomy or glaucoma drainage implant to lower pressure adequately.

PROGNOSIS

Good if prompt treatment is initiated for acute attack; poorer for chronic cases but depends on extent of optic nerve damage and subsequent intraocular pressure control. ▼

12.4 NEOVASCULAR GLAUCOMA

A form of secondary angle-closure glaucoma in which neovascularization of the iris and angle causes occlusion of the trabecular meshwork (Fig. 12.7).

ETIOLOGY

Ocular ischemia

Most commonly seen with:

- Proliferative diabetic retinopathy
- Central retinal vein occlusion
- Carotid occlusive disease
- Tumors
- Chronic inflammation
- Chronic retinal detachment

SYMPTOMS AND SIGNS:

Decreased visual acuity

Abnormal blood vessels on iris and angle, particularly at pupillary margin

Increased IOP

Optic nerve cupping and visual field defects

May have corneal edema

Spontaneous hyphema or retinal lesions

WORK-UP

Complete ophthalmic history and eye examination with attention to cornea, tonometry, anterior chamber, gonioscopy, iris and ophthalmoscopy.

Consider medical consultation for systemic diseases, including Doppler scans of carotid arteries to rule out carotid occlusive disease.

MANAGEMENT

Topical steroid (Prednisolone acetate 1% qid) and cycloplegic agent (Atropine 1% bid) for inflammation.

Topical glaucoma medications excluding prostaglandine analogues (Xalatan, Travatan) and Pilocarpine.

Usually requires laser photocoagulation for retinal ischemia if the cornea is clear; if the cornea is cloudy may require peripheral cryotherapy.

Neovascular glaucoma with elevated IOP despite maximal medical therapy may require glaucoma filtering surgery, a glaucoma drainage implant or a cyclodestructive procedure.

POINTS TO REMEMBER

Pilocarpine and Xalatan or Travatan are contraindicated due to causing inflammation

PROGNOSIS

Poor; the rubeotic vessels may regress with appropriate therapy, but most causes of neovascularization are chronic progressive diseases.▼

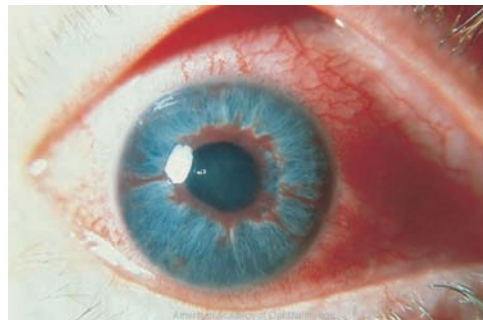


Fig.12.7 Neovascular glaucoma

13. PEDIATRIC OPHTHALMOLOGY



13.1 RETINOPATHY OF PREMATUREITY (ROP)

Other name: retrolental fibrosis

ROP is a disease process occurring in premature infants in which abnormal retinal neovascularization (Fig. 13.1, 13.2) occurs at the intersection of the mature and immature retina leading to cicatricial changes including macular traction, retinal detachment and phthisis (Fig. 13.3).

ETIOLOGY:

The cause of ROP is multifactorial, but it is believed that in an immature retina hyperoxia leads to vasoconstriction and secondary retinal ischemia, liberation of vascular growth factors and growth of new retinal vessels.

ASSOCIATE FACTORS:

- ▲ Birth weight and gestational age: the incidence and severity of ROP are inversely related to birth weight and gestational age.
- ▲ Oxygen therapy: oxygen has long been implicated as a major factor; however, there is no direct relationship to ROP. It is most likely a combination of hyperoxia and hypoxia that contributes to the development of ROP.
- ▲ Sepsis
- ▲ Exchange transfusions

- ▲ Necrotizing enterocolitis
- ▲ Bronchopulmonary dysplasia

SIGNS AND SYMPTOMS:

- Strabismus
- Leukocoria
- Glaucoma

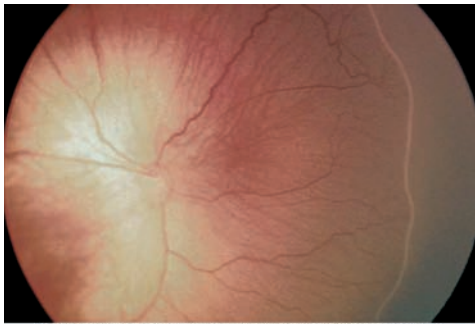


Fig.13.1 Retinopathy of prematurity - demarcation line between vascularized (mature) and non-vascularized (immature) retina

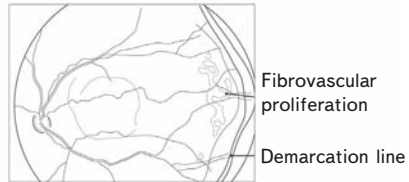
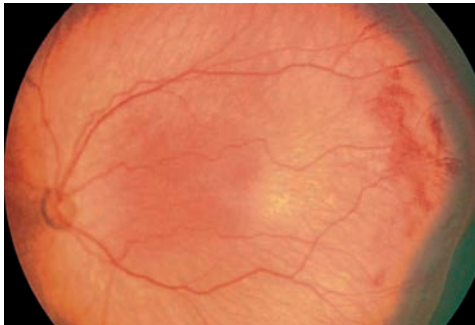


Fig.13.2 Retinopathy of prematurity with neovascularization

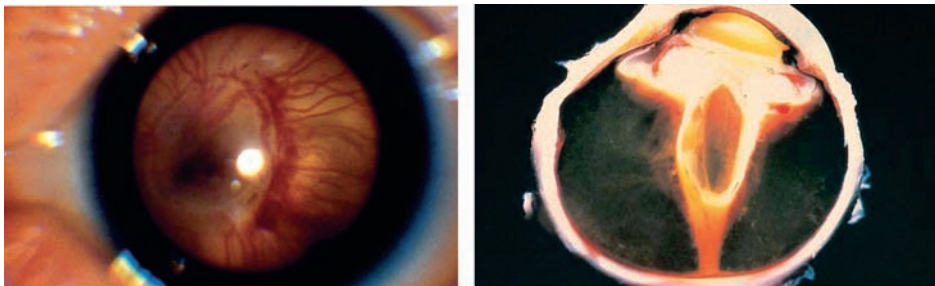


Fig.13.3 Tractional detachment in retinopathy of prematurity

DEMOGRAPHICS

- ▲ All infants who weigh less than 1,500g or are younger than 34 weeks' gestational age should be examined for ROP.
- ▲ Children should be examined at 32 weeks' gestational age and every 2 weeks thereafter until the retina is fully mature.
- ▲ Low-birth-weight infants are at much higher risk for development of ROP.

DISEASE COURSE

- ▲ Progression
 - ▲ Spontaneous resolution at any stage of the disease
- Chronic cicatricial changes of ROP include failure to vascularize the periphery, retinal folds, dragging of the macula temporally, retinal pigment epithelial changes, traction or rhegmatogenous retinal detachment.

TREATMENT AND MANAGEMENT

- ▲ Treatment of ROP with cryotherapy may prevent progression of disease. Patients are treated with cryotherapy or indirect ophthalmoscopically delivered laser therapy to avascular retina when there is threshold disease.
- ▲ Threshold disease is defined as five or more contiguous clock hours and plus disease (vascular tortuosity and dilation).
- ▲ Treatment of children with these stages of disease can lead to regression and prevent progression of disease with subsequent loss of vision.
- ▲ Children with a history of ROP are at high risk for development of strabismus and refractive errors including myopia and astigmatism and should be followed closely in the first 5 years of life.

DIFFERENTIAL DIAGNOSIS:

- Coat's disease
- Toxocariasis ▼

13.2 STRABISMUS

Ocular misalignment that may be idiopathic or acquired; horizontal or vertical; comitant (same angle of deviation in all positions of gaze) or incomitant (angle of deviation varies in different positions of gaze [paralytic or restrictive causes]); latent, manifest or intermittent.

STRABISMUS EVALUATION

HISTORY

Prenatal history: maternal illness, smoking, alcohol, drug use or diabetes

Birth history: type of delivery, anoxic or hypoxic episodes, prematurity with birth weight, gestational age, presence of ventricular hemorrhage, duration of hospitalization.

Onset

- ▲ Age at onset; related trauma, illness; frequency, pattern and regression of deviation; predisposing factors (sunlight, illness, fatigue); alleviating factors; associated symptoms (headache, photopsia, neurologic abnormalities).
- ▲ Past medical illness
- ▲ Family history of strabismus
- ▲ Review of systems
- ▲ Weight change, fatigability, hypertension, diabetes, headache, neurologic symptoms
- ▲ Strabismus evaluation
- ▲ Sensorimotor examination

Screening Techniques:

Cover/uncover test for heterophorias/ tropia

Technique: an opaque occluder is used to cover one eye. The cover is then removed and the eye is observed. Movement of the observed eye indicates that a phoria is present.

In heterophoria fusion is maintained by binocular vision.

CONGENITAL (INFANTILE) ESOTROPIA (Fig. 13.4)

Esotropia is present before 6 months of age.

ETIOLOGY

Exact cause is unknown; two theories exist:

- ▲ Primary defect in sensory fusion mechanism caused by:
 - Coloboma
 - Lid hemangioma
- ▲ Primary defect in motor fusion

SIGNS AND SYMPTOMS:

Early onset: before 6 months of age

Large deviation: usually greater than 45 prism diopters

Alternate fixation or cross fixation

DEMOGRAPHICS

- ▲ By definition, occurs within 6 months of age
- ▲ Family history of strabismus is common

OPHTHALMIC FINDINGS:

- ▲ Large-angle strabismus
- ▲ Alternate fixation
- ▲ Cross-fixation: can have the appearance of bilateral sixth-nerve palsy
- ▲ Amblyopia uncommon
- ▲ Refractive error less than +2.00 sphere
- ▲ Findings that develop later:
 - Inferior oblique overaction
 - Dissociated vertical deviation (DVD)
 - Latent nystagmus

SYSTEMIC FINDINGS:

None

DISEASE COURSE

- ▲ Untreated patients have good vision with free alternation of fixation. They have absence of binocular function.
- ▲ Treated patients may have peripheral fusion, and gross stereopsis can develop

TREATMENT AND MANAGEMENT

- ▲ Eliminate amblyopia with occlusion therapy
- ▲ Trial of spectacles for refraction of +1.50 sphere or greater.
- ▲ Surgical correction is usually required
- ▲ Timing of surgery is controversial: some authorities advocate early surgery to yield better sensory fusion; others recommend surgery by the age of 2 years. Most surgeons operate on patients 9 to 16 months of age.
- ▲ Surgical procedure: bimedial recession
- ▲ For deviation larger than 45 prism diopter combine bimedial surgery with a lateral rectus recession.
- ▲ Inferior obliques must be weakened if overaction is present
- ▲ Must follow patient postoperatively for development of amblyopia and accommodative esotropia.
- ▲ 30-40% of children need a second surgical procedure (for residual esotropia, DVD, or oblique dysfunction) some time in their life.
- ▲ Botulinum toxin can be used for weakening medial rectus.

MEDICATIONS:

None

FOLLOW-UP

Every 6 months for 6 years to watch for amblyopia and recurrent strabismus.

ACCOMMODATIVE ESOTROPIA (Fig. 13.5)

Accommodative esotropia is an acquired esotropia occurring between 18 and 36 months of age, resulting from excessive accommodation in hypermetropic children.

ETIOLOGY

- ▲ A synkinetic relationship exists between accommodation and convergence.
- ▲ Some hypermetropic children accommodate to focus the image, leading to convergence and esotropia.

SIGNS AND SYMPTOMS:

- ▲ Crossed eyes: esotropia
- ▲ Deviation often intermittent at first
- ▲ Deviation often starts at near fixation and progresses to occur at distance fixation .
- ▲ Most frequent when the child is ill or fatigued
- ▲ Patient may complain of diplopia before development of suppression and amblyopia

DEMOGRAPHICS

- ▲ Usual onset at 18 to 36 months, but may occur from 6 months to 7 years
- ▲ Family history of strabismus is common

OPHTHALMIC FINDINGS:

- ▲ Esotropia: usually 20 to 40 prism diopters
- ▲ Hypermetropia
- ▲ Amblyopia is common
- ▲ Stereopsis may be poor if esotropia is long-standing, or may be normal if esotropia is intermittent and properly treated.

SYSTEMIC FINDINGS:

None

SPECIAL TEST

Cycloplegic refraction is essential for proper diagnosis. Use cyclopentolate 1% two times, then refract after 30 minutes or use atropine 1% solution for 3 nights before examination

DISEASE COURSE

- ▲ If left untreated, amblyopia develops and becomes irreversible by age 6 years.
- ▲ Stereopsis is lost if untreated.
- ▲ With treatment, vision can be normal and normal stereopsis can be maintained.
- ▲ Hypermetropia decreases with age and many children can be weaned from the use of glasses by age 10 years.

TREATMENT AND MANAGEMENT:

Optical: prescribe full hyperopic refraction. Spectacles must be worn full-time and often control the deviation completely. As the child ages the hypermetropic refractive error decreases and often the spectacles can be weaned away from the patient between the ages of 10 to 12 years.

Pharmacologic management: anticholinesterase drops - Pilocarpine 1%, induce accommodation locally by eliminating blur, which stimulates central accommodation and convergence. Because of side effects, they are used only when spectacle therapy fails.

Surgical management: surgery should be performed only in cases of partly accommodative esotropia (when spectacles fail to completely align the eyes) or when noncompliance prevents spectacles from being worn. Surgery performed on patients who can be treated with optical correction results in consecutive exodeviations later in life, when hypermetropia decreases. In partly accommodative esotropia

the amount of surgery performed should be only for the residual deviation that is not corrected by spectacles.

Amblyopia: therapy must be concurrent with strabismus treatment.

FOLLOW-UP:

- ▲ Amblyopia must be monitored and treated.
- ▲ Binocularity is monitored at each visit.
- ▲ If the eyes are straight with spectacles and amblyopia reverses, follow up every 4 to 6 months. Repeat cycloplegic refraction annually.
- ▲ Wean patient away from spectacles between ages 8-11 years.

EXODEVIATION (Fig. 13.6)

A divergent alignment of the visual axes is an exodeviation. The deviation may be kept latent by fusion (exophoria) and may be intermittently present (intermittent exotropia) or manifest at all times (constant exotropia).

ETIOLOGY

- ▲ Mechanical factors, craniofacial disorders
- ▲ Imbalance of convergence-divergence mechanisms
- ▲ Sensory exotropia occurs in poor vision

SIGNS AND SYMPTOMS:

- ▲ Exotropia is worse when patient is fatigued
- ▲ Occasional diplopia
- ▲ Asthenopia

- ▲ Squinting
- ▲ Photophobia

DEMOGRAPHICS

Most common in children older than 2 years of age.

DISEASE COURSE

Intermittent exotropia may progress to constant exotropia over time.

SYSTEMIC FINDINGS:

- ▲ Congenital exotropia is commonly seen in children with underlying neurologic abnormalities. Children with congenital exotropia should have pediatric neurologic evaluation.
- ▲ Cranial facial anomalies.

SPECIAL TEST

Prolonged occlusion tests: occluding one eye for 30 to 45 minutes disassociates the eyes maximally by suspending fusion. This allows measurement of maximum deviation: test deviation at distance and near.

DISEASE COURSE

- ▲ Exophorias may produce eye strain
- ▲ Exophorias may progress to intermittent deviation
- ▲ Intermittent exodeviation may first involve distance fixation, progressing to exotropia at near with subsequent decrease in stereoacuity.

TREATMENT

- ▲ Measure convergence amplitude: if decreased, prescribe convergence exercises.
- ▲ Intermittent exotropia: treat amblyopia and refractive errors. Patients younger than 3 can be alternately occluded for a percentage of waking hours as a form of antisuppression therapy. Minus lenses (-1.50 to -3.00 D sphere) can be used to stimulate accommodative convergence to control exotropia. Patients with convergence insufficiency can be given orthoptic exercises to improve convergence fusional amplitudes.
- ▲ Surgical treatment is reserved for cases of intermittent exotropia that is increasing in magnitude and frequency, and is used for cases of constant exotropia.
- ▲ Divergence excess exotropia should be treated by bilateral lateral rectus recessions.
- ▲ Constant exotropia or sensory exotropia can be treated by recession or resection procedures. Convergence insufficiency should be treated by bilateral medial resection.

MEDICATIONS:

None

FOLLOW-UP

Up to 30% of patients treated with surgery develop recurrent exodeviation. This is more common in cases of sensory exotropia. ▼

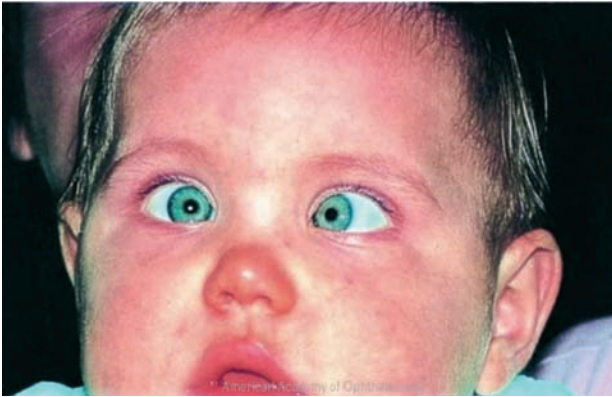
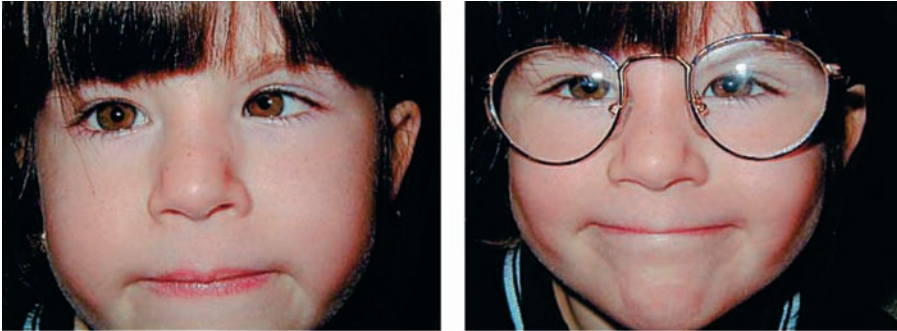
Fig.13.4 Classic congenial esotropia



© 2005 Elsevier Ltd. Spalton et al: Atlas of Clinical Ophthalmology 3e

Fig.13.5 Concomitant strabismus

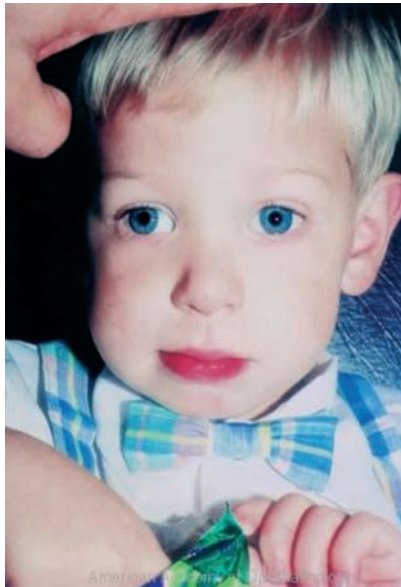

Fig.13.6 A 3-year-old-boy with intermittent exotropia

13.3 AMBLYOPIA

SYMPTOMS:

Decreased vision in one eye

Amblyopia occasionally occurs bilaterally as a result of bilateral visual deprivation (e.g. congenital cataracts, high refractive errors).

A history of patching, strabismus and/or muscle surgery as a child may be elicited.

CRITICAL SIGNS:

Poorer vision in one eye that is not improved with refraction and not entirely explained by an organic lesion. The decrease in vision develops during the first decade of life and does not deteriorate or improve thereafter.

POINTS TO REMEMBER

Amblyopia, even when severe, rarely causes a significant relative afferent pupillary defect.

ETIOLOGY

- Anisometropia (a difference in refractive error between the two eyes).
- Strabismus (the eyes are not straight. Vision is worse in the nonfixating eye. Strabismus can lead to, or be the result of, amblyopia).
- Occlusion (ptosis - congenital or secondary (e.g. eyelid hemangioma) or iatrogenic (e.g. patching)).
- Organic (media opacity (e.g. cataract, corneal scar, persistent hyperplastic primary vitreous, retinal or macular lesion)).

WORK-UP

1. History: eye problem in childhood, particularly misaligned eyes? patching or muscle surgery as a child?

2. Complete ocular examination to rule out an organic cause for a reduced vision. Carefully check the pupils, optic disc and macula.
3. Cover-uncover test to evaluate eye alignment.
4. Cycloplegic refraction.

TREATMENT / FOLLOW-UP

A. Patient < 9-11 years of age:

1. Spectacle correction if significant anisometropia is present.
2. Full-time patching (Fig. 13.7) over the eye with better vision for one week per year of age (e.g. 3 weeks for a 3-year-old), followed by a repeat examination.
3. Continue patching as above until the vision is equalized, or if vision does not improve after three compliant cycles of patching. If a recurrence of ambliopia is likely, then part-time patching (e.g. 2-6 hours/day) is used until the child reaches 9-11 years of age.
4. In noncompliant patients consider placing atropine 0,5-1% tid into the better eye to reduce its vision. This may succeed only if the vision of the better-seeing eye is reduced below that of the poorer-seeing eye.
5. If occlusion ambliopia (e.g. a decrease in vision in the patched eye) develops, patch the eye with better vision for a short period of time (e.g. 1 day per year of age) and repeat examination.
6. In strabismic ambliopia delay strabismus surgery until the vision in the two eyes is equal, or maximal vision has been obtained in the amblyopic eye.

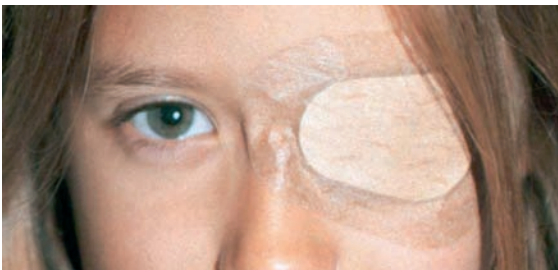

Fig.13.7 Full-time patching

B. Patients older than 11 years of age:

No treatment is useful. Protective glasses should be worn at all times if only one eye has good vision.

POINTS TO REMEMBER

- ▲ Pirate patches and patches worn over glasses are less effective than patches that are placed directly over the eye and adhere to the skin.
- ▲ Convincing the parent (usually mother) of the dangers of lifelong reduced vision if the patching is not done may be necessary, to reinforce a commitment to treat the child firmly. ▼

13.4 CONGENITAL NASOLACRIMAL DUCT OBSTRUCTION**ETIOLOGY**

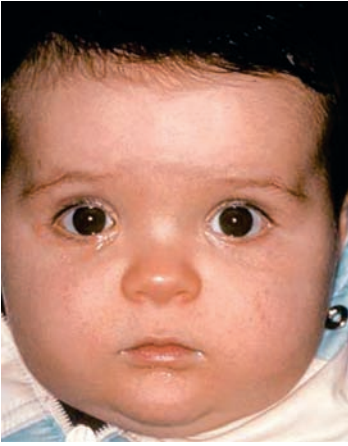Usually the result of an imperforate membrane at the distal end of the nasolacrimal duct.

SIGNS

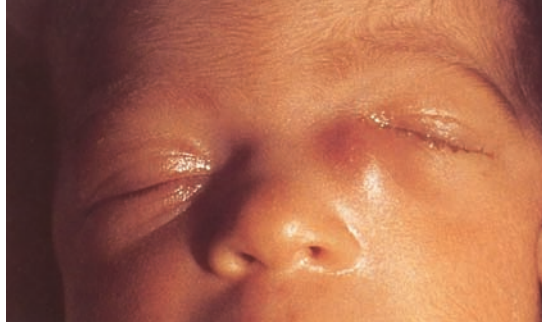Wet-looking eye or tears flowing over the eyelid (Fig. 13.8); moist or dried mucopurulent material on the eyelashes (predominantly medially), and reflux of mucoïd or mucopurulent material from the punctum when pressure is applied over the lacrimal sac, where the lower eyelid abuts the nose.

Erythema of the surrounding skin; redness and swelling of the medial canthus (Fig. 13.9).

Preseptal cellulitis or dacryocystitis may rarely develop.

**Fig.13.8**

Congenital blockage of the nasolacrimal duct

Fig.13.9 Dacryocystitis

POINTS TO REMEMBER

Nasolacrimal duct obstruction may be associated with an otitis or pharyngitis.

DIFFERENTIAL DIAGNOSIS

- Conjunctivitis

Red eye, discharge. Usually acute, follicles or papillae may not or may not be present on the inferior tarsal conjunctiva, tearing is not chronic).

- Congenital anomalies of the upper lacrimal drainage system (atresia of the lacrimal puncta or canaliculus).

- Mucocele of the lacrimal sac (possibly visible is a bluish, cystic, non-tender mass located just below the medial canthal angle. Caused by both a distal and a proximal obstruction of the nasolacrimal apparatus).

- Other causes of tearing (e.g., entropion/trichiasis, corneal defects, foreign body under the upper lid, congenital glaucoma)

WORKUP

1. Exclude other causes of tearing, (blepharitis/conjunctivitis/keratitis) with slit-lamp or penlight examination. Make sure the corneal diameter is not large, and ruptures in Descemet's membrane are not present (congenital glaucoma).

2. Palpate over the lacrimal sac; reflux of mucoïd or mucopurulent discharge from the punctum confirms the diagnosis.

TREATMENT

1. Digital pressure to canalicular system b.i.d. to q.i.d. The parent is taught to place his or her index finger over the child's common canaliculus (inner corner of the eye) and to apply pressure several times a day.
2. Erythromycin ointment b.i.d. disturbing as needed, to control mucopurulent discharge if present.
3. In the presence of acute dacryocystitis, a systemic antibiotic is needed, Cephalosporin P/O QID for 7 days.

Most cases open spontaneously with this regimen by 1 year of age. If this is not the case:

4. Nasolacrimal duct probing is usually performed after age 10 months, earlier if recurrent or persistent infections of the lacrimal system develop, or at the request of the parents. Prior to duct probing, superior punctal closure with a chalazion clamp, followed by forced irrigation into the lower punctum, may be performed to hydrostatically open the occlusion preventing the need for probing. If this is unsuccessful, during the same anesthetic session probing may be performed. Most obstructions are corrected after the initial probing; others may require repeated probings. If patency is not established after two probings, place silicone tubing in the nasolacrimal duct and leave it in place for three weeks.

FOLLOW-UP

Follow up by phone calls. The child should return if the situation becomes worse or acute dacryocystitis is present, or if the parents are unsure. ▼

14. TRUE OCULAR EMERGENCY

14. 1 CHEMICAL OR THERMAL BURN

Ocular tissue destruction including cornea (epithelium and stroma) due to chemical (acid or base) or thermal (e.g. welding, intense sunlight, tanning lamp) injury; alkali causes most severe injury and may cause perforation. May be from striking an alkaline battery such that the resultant burst of the alkaline core strikes the eye (Fig. 14.2, 14.2).

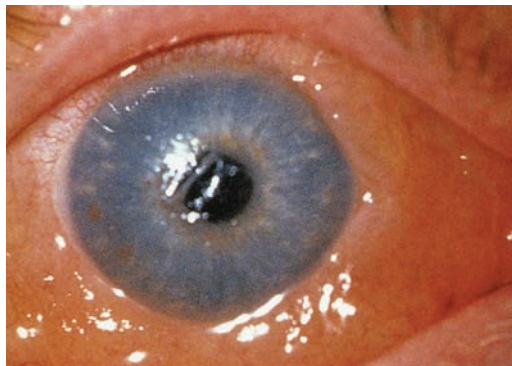


Fig.14.1 Alkali Burn . The acute stage, showing conjunctival chemosis and mild corneal opacification.

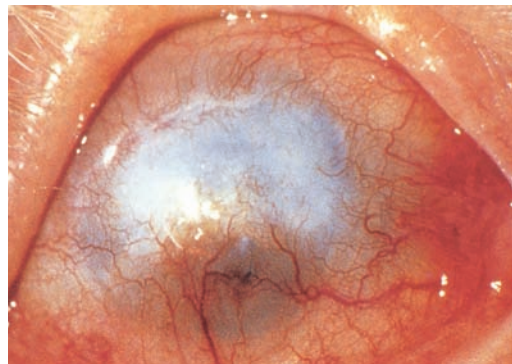

Fig.14.2 Alkali Burn. The chronic stage, showing total corneal opacification and vascular ingrowth in a blind eye.

SIGNS AND SYMPTOMS:

- Pain
- Foreign body sensation
- Photophobia
- Tearing
- Red eye
- Normal or decreased visual acuity
- Conjunctival injection
- Ciliary injection
- Epithelial defects that stain with fluorescein
- Scleral or limbal blanching due to ischemia in severe chemical burns

MANAGEMENT

OPHTHALMIC EMERGENCY

- ▲ Immediate copious irrigation with clean available water or saline for 30 minutes.
- ▲ Measure pH after irrigation; continue irrigation until pH is neutralized. May be deceptive as conjunctival blebs can occur which contain higher PH alkaline fluid.
- ▲ Remove any chemical particulate matter from the eye surface and evert lids to sweep fornices and blebs with sterile cotton swab. Then re-measure pH.
- ▲ Topical lubrication with preservative-free artificial tears or Solcoseryl 20% ophthalmic gel q.1h and Solcoseryl at bedtime.
- ▲ Broad spectrum topical antibiotic Moxifloxacin 0,5% qid.
- ▲ Cycloplegic agents (Cyclopentolate 1%, Scopolamine 0,25% or Atropine 1% bid to qid, depending on severity)
- ▲ For more severe damage, consider topical steroids (Prednisolone acetate 1% up to q.2h then taper; only use during the first week).
- ▲ Topical Citrate 10% qid, or
Sodium ascorbate 10% qid and 2g po qid
Acetylcysteine (Mucomyst) up to q.4h
- ▲ Treat symblepharon: lyse with glass rod; consider vitamin A to improve goblet cell function.
- ▲ Often requires treatment of increased intraocular pressure.

- ▲ In severe cases surgery may be required, including symblepharon lysis, conjunctival and mucous membrane or limbal stem cell transplantation, and tarsorrhaphy; later consider penetrating keratoplasty or keratoprosthesis. ▼

14.2 CENTRAL RETINAL ARTERY OCCLUSION (CRAO) (Fig. 14.3)

Disruption of the vascular perfusion in the central retinal artery leading to global retinal ischemia.

ETIOLOGY

Emboli (only visible in 20-40% of cases) or thrombus at the level of lamina cribrosa. Other causes:

- Temporal arteritis
- Leukoemboli in collagen-vascular diseases
- Fat emboli
- Trauma (through compression, spasm or direct vessel damage)
- Hypercoagulation disorders
- Syphilis
- Mitral valve prolapse
- Particles (talc) from IV drug abuse
- Compressive lesions
- Primary open-angle glaucoma

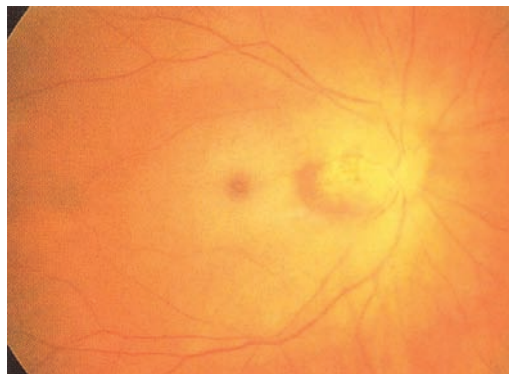


Fig. 14.3 Central retinal artery occlusion

EPIDEMIOLOGY

Usually occurs in elderly patients; associated with:

- Hypertension
- Carotid occlusive disease
- Diabetes mellitus
- Cardiac valvular disease

CRAO is more common than branch retinal artery occlusion (BRAO) or cilioretinal artery occlusion. Bilateral involvement is rare.

SYMPTOMS:

Sudden, unilateral, painless, profound loss of vision. May have history of amaurosis fugax (episodes of loss of vision), prior cerebrovascular accidents (CVA), or transient ischemic attacks (TIAs).

SIGNS:

- Decreased VA in the count fingers (CF) to light perception (LP) range
- Positive APD
- Diffuse retinal whitening and arteriole constriction with segmentation (“box caring”) of blood flow
- Cherry-red spot in the macula (thin fovea allows visualization of the underlying choroidal circulation)

In ciliary retinal artery-sparing CRAO small wedge-shaped area of perfused retina may be present temporal to the optic disc, spare the foveola, in which case visual acuity improves to 20/50 or better.

DIFFERENTIAL DIAGNOSIS

- Ophthalmic artery occlusion
- Commotio retinae
- Cherry-red spot due to inherited metabolic or lysosomal storage disease.

WORK-UP

- ▲ Complete ophthalmic history and eye examination with attention to pupils, fundus examination.

- ▲ Check blood pressure.
In patients > 50 years old check erythrocyte sedimentation rate (ESR) to rule out arteritic ischemic optic neuropathy.

- ▲ Medical consultation for complete cardiovascular evaluation including electrocardiogram, echocardiogram, and carotid Doppler studies.

MANAGEMENT

OPHTHALMIC EMERGENCY

Treatment for central retinal artery occlusion should be immediate. Irreversible retinal damage is said to occur after 90 minutes, but treatment should be considered in patients presenting within 24 hours of onset. The goals of treatment are to restore retinal blood flow and to move a potential retinal embolus distally. Emergency treatment is initiated as follows:

1. Lower intraocular pressure to improve retinal perfusion in one or more of the following ways:
 - a) Massage the globe digitally and forcefully using enough pressure to dent a tennis ball. In addition to lowering the intraocular pressure, this might also dislodge an embolic plaque.
 - b) Administer acetazolamide (500 mg po).
 - c) Topical ocular hypotensive drops: b-blockers (Timolol 0,5% 1gtt q.15 min x 2, repeat as necessary).
 - d) Consider performing anterior chamber paracentesis.

2. Produce arterial dilation by having the patient breathe into a paper bag and consider admission to hospital for carbogen treatment (95% oxygen, 5% carbon dioxide for 10 minutes q.2h for 24-48 hours) to attempt to increase oxygenation and induce vasodilation.
3. IM injection of Papaverine 40 mg.

Unproven treatments include hyperbaric oxygen, antifibrinolytic drugs, retrobulbar vasodilators, and sublingual nitroglycerine.

If arteritic ischemic optic neuropathy is suspected: systemic steroids (Methylprednisolone 1g IV qd in divided doses for 3 days, then prednisone 60-100 mg po qd with a slow taper; decrease by no more than 2,5 – 5,0 mg/wk)

PROGNOSIS

Retinal pallor fades and circulation is restored over several weeks. Poor prognosis: most have persistent severe visual loss with constricted retinal arterioles and optic atrophy (positive APD). Rubeosis (20%) and disc or retinal neovascularization (2-3%) can occur. Presence of visible embolus associated with increased mortality. ▼

14.3 PRIMARY ANGLE-CLOSURE GLAUCOMA

Glaucoma due to obstruction of trabecular meshwork by peripheral iris; classified as acute, subacute (intermittent) and chronic.

ETIOLOGY/ MECHANISM

Pupillary block (most common): lens-iris apposition interferes with aqueous flow and causes iris to bow forward and occlude the trabecular meshwork (Fig. 14.4).

Plateau iris syndrome (without pupillary block): peripheral iris occludes angle in patients with atypical iris configuration (anteriorly positioned peripheral iris will steep insertion due to anteriorly rotated ciliary processes).

EPIDEMIOLOGY

Female predilection (4:1); higher incidence in Asians and Eskimos; approximately 5% of the general population over 60 years old have occludable angles, 0,5% of these develop angle-closure; usually

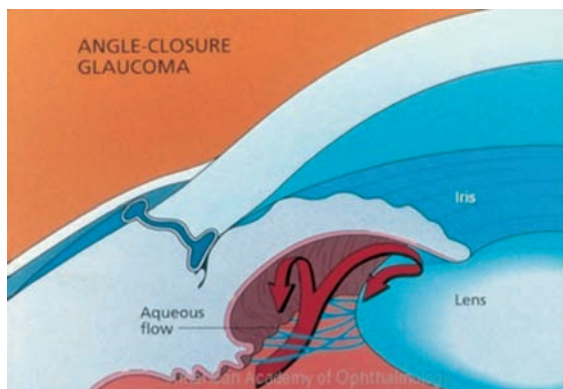


Fig.14.4 Acute angle-closure glaucoma

bilateral (develops in 50% of untreated fellow eye within 5 years); associated with:

- hyperopia
- nanophthalmos
- anterior chamber depth less than 2,5 mm
- thicker lens
- lens subluxation

SYMPTOMS:

Acute angle-closure:

1. Colored halos around lights to differentiate from patients with cataract
2. Red eye
3. Photophobia
4. Blurred vision
5. Headache or brow ache becomes severe
6. Nausea, vomiting

Subacute angle-closure:

- mild headache and blurred vision in the morning or photophobia upon awaking;
- may be asymptomatic or have symptoms of acute form but less severe;
- episodes evolve over the course of days or weeks and resolve spontaneously.

Chronic angle-closure:

Asymptomatic; may have decreased vision or constricted visual fields in late stages.

SIGNS:

Acute angle-closure (Fig. 14.5):

- Decreased visual acuity

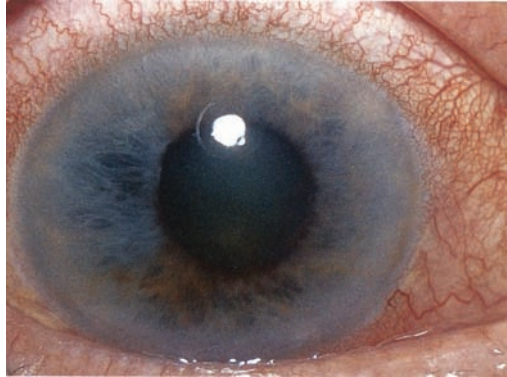


Fig.14.5 Acute angle-closure glaucoma

- Increased intraocular pressure
- Ciliary injection
- Corneal edema
- Anterior chamber cells and flare
- Shallow anterior chamber
- Narrow angles on gonioscopy
- Mid-dilated, nonreactive pupil, iris bombe
- May have signs of previous attacks including sector iris atrophy, anterior subcapsular lens opacities, dilated irregular pupil and peripheral anterior synechiae.

Subacute and chronic angle-closure:

- Narrow angles
- May have increased IOP, peripheral anterior synechiae, anterior subcapsular lens opacities, visual field defects and optic nerve cupping.

WORK-UP

- ▲ Complete ophthalmic history and eye examination with attention to pupils, cornea, tonometry, anterior chamber, iris, indentation gonioscopy, lens and ophthalmoscopy.
- ▲ Check visual fields

MANAGEMENT

ACUTE ANGLE-CLOSURE: OPHTHALMIC EMERGENCY

- ▲ Topical b-blocker (Timolol [Timoptic] 0,5% q. 15 minutes x2, then bid)
α-agonist (Apraclonidine [Iopidine] 1% q. 15 minutes x2), and topical steroid (Prednisolone acetate 1% q. 15 minutes x4, then q. 1h)
Topical miotic (Pilocarpine 1-2% q. 15 minutes x3)
- ▲ Usually not effective if intraocular pressure is >40 mm Hg due to iris sphincter ischemia.

POINTS TO REMEMBER

- ▲ Pilocarpine will be instilled no more than 3 times, since frequent instillation will exacerbate the situation due to forward displacement of the lens-iris diaphragm.
- ▲ Systemic acetazolamide in case the patient does not have allergy on sulfa drugs.
Diamox 500 mg po, then bid.
- ▲ Hyperosmotic glycerol 50% po. put in glass with ice and juice. Makes it easier to tolerate
- ▲ Laser peripheral iridotomy with or without iridoplasty. This can be done immediately without waiting for attack to be broken medically. Usually requires application of topical glycerin (Ophthalgan) to clear corneal edema for adequate visualization for laser. Put in topical anesthetic first, since glycerine is painful.
- ▲ Prophylactic laser peripheral iridotomy in fellow eye with narrow angle to prevent an acute attack in the future.
- ▲ If unable to perform laser peripheral iridotomy, consider surgical iridectomy.

- ▲ Plateau iris syndrome may require long-term miotic therapy and peripheral iridectomy to reduce the risk of pupillary block; consider argon laser, iridoplasty or gonioscopy.

* Cataract extraction or clear lensectomy may be necessary if narrow angle glaucoma is uncontrolled.

SUBACUTE AND CHRONIC ANGLE-CLOSURE

- ▲ Laser peripheral iridotomy even without evidence of pupillary block.
- ▲ Treatment of increased IOP; may require trabeculectomy or glaucoma drainage implant to lower pressure adequately.

PROGNOSIS

Good if prompt treatment is initiated for acute attack; poorer for chronic cases but depends on extent of optic nerve damage and subsequent intraocular pressure control. ▼

15. ENDOPHTHALMITIS

Intraocular infection; may be acute, subacute or chronic; localized or involving anterior and posterior segments.

ETIOLOGY

POSTOPERATIVE (70%)

Acute postoperative (<6 weeks after surgery) (Fig. 15.1, 15.2)

94% of the cases – gram-positive bacteria, including coagulase-negative staphylococci (70%), *Staphylococcus aureus* (10%), *Streptococcus* species (11%), and only 6% of the cases – gram-negative organisms.

Delayed postoperative (>6 weeks after surgery) (Fig. 15.3)

Propionibacterium acnes, coagulase-negative staphylococci and fungi (*Candida* species).

Conjunctival filtering bleb associated

Streptococcus species (47%), coagulase-negative staphylococci (22%), *Haemophilus influenzae* (16%).

POST-TRAUMATIC

Bacillus (*B.cereus*) species (24%), *Staphylococcus* species (39%) and gram-negative organisms (7%)

Untreated corneal ulcer especially with contact lens wearers (Fig. 15.4)

ENDOGENOUS

Rare, usually fungal (*Candida* species) (Fig. 15.5); bacterial endogenous is usually due to *Staphylococcus aureus* and gram-negative bacteria; seen in debilitated, septicemic or immunocompromised patients, especially after surgical procedures.

EPIDEMIOLOGY

Incidence of endophthalmitis following penetrating trauma is 3-7%, may be as high as 30% after injuries in rural settings; risk factors include retained intraocular foreign body, delayed surgery (>24 hours), rural settings (soil contamination), disrupted crystalline lens.

Incidence of endophthalmitis following cataract surgery is less than 0,1%.

RISK FACTORS:

For Postoperative and Post-traumatic

- Loss of vitreous
- Disrupted posterior capsule
- Poor wound closure
- Prolonged surgery

SYMPTOMS:

- Pain
- Photophobia
- Discharge
- Red eye
- Decreased vision
- May be asymptomatic or have chronic uveitis appearance in delayed onset and endogenous cases.

SIGNS:

- Decreased visual acuity (usually severe; only 14% of patients had better than 5/200 vision)
- Lid edema

- Proptosis
- Conjunctival injection
- Chemosis
- Wound abscess
- Corneal edema
- Keratic precipitates
- Anterior chamber cells and flare
- Hypopion
- Poor red reflex
- May have positive Seidel test result and other signs of an open globe.

DIFFERENTIAL DIAGNOSIS

Uveitis, sterile inflammation (usually from prolonged intraoperative manipulations, especially involving vitreous, contaminants on IOL implant or surgical instruments, retained lens material or rebound inflammation after sudden decrease in postoperative medications), intraocular foreign body, intraocular tumor, sympathetic ophthalmia, anterior segment ischemia (from carotid artery disease [ocular ischemic syndrome] or following muscle surgery [usually on three or more rectus muscles in same eye at the same surgery]).

WORK-UP

- ▲ Complete ophthalmic history and eye examination with attention to visual acuity, surgical incision integrity, conjunctiva, cornea, tonometry, anterior chamber, vitreous cells, red reflex and ophthalmoscopy.
- ▲ b-scan ultrasonography if unable to visualize the fundus.
- ▲ Medical consultation for endogenous endophthalmitis.

MANAGEMENT: OPHTHALMIC EMERGENCY

Acute postoperative endophthalmitis

- ▲ If vision is better than light perception (>LP), then anterior chamber and vitreous tap for collection of specimens for culture, and injection of intravitreal antibiotics.
- ▲ If vision is LP only, then anterior chamber tap, pars plana vitrectomy, and injection of intravitreal antibiotics; should be managed by vitreoretinal specialist.
- ▲ Intravitreal antibiotics or steroids
- ▲ Subconjunctival antibiotics or steroids
 - Cefazoline (100 mg)
 - Ceftazidime (100 mg) or Gentamicin (20 mg)
 - Dexamethasone (1mg)
- ▲ Broad spectrum fortified topical antibiotics (alternate every 30 minutes):
 - Cefazolin (50mg/ml q.1h)
 - Ceftazidime (50mg/ml q.1h)
- ▲ Topical steroid (Prednisolone acetate 1% q.1-2h initially) and cycloplegic agent (Atropin 1% tid or Scopolamine 0,25% qid)
- ▲ Systemic intravenous antibiotics for marked inflammation, severe cases or rapid onset:
 - Cefazolin (1g IV q.8h)
 - Ceftazidime (1g IV q.12h)

Subacute, Delayed, Endogenous, Filtering Bleb Associated, and Post-traumatic endophthalmitis

- ▲ Intravitreal antibiotics or steroids similar to acute postoperative guidelines (see above); add Amphotericin B (0,005 mg/ml) if endogenous fungal, or delayed onset and presumed fungal etiology.

- ▲ Subconjunctival antibiotics or steroids similar to acute postoperative guidelines (see above).
- ▲ Broad spectrum fortified topical antibiotics similar to acute postoperative guidelines (see above); add Amphotericin B 1,0-2,5 mg/ml q.1h or Natamycin 50 mg/ml q.1h if fungal (poor penetration).
- ▲ Topical steroid (Prednisolone acetate 1% q.1-2h initially) and cycloplegic agent (Atropin 1% tid)
- ▲ Systemic intravenous antibiotics for marked inflammation similar to acute postoperative guidelines (see above).
- ▲ Systemic antifungal agents (Amphotericin B 0,25-1,0 mg/kg IV divided equally q.6h) if a disseminated disease exists.
- ▲ Delayed postoperative endophthalmitis may require partial or total capsulectomy, pars plana vitrectomy, or IOL removal or exchange.
- ▲ Consider repeat tap (or pars plana vitrectomy) and intravitreal injections if clinical picture is worse after 48-72 hours.
- ▲ Tailor antibiotic choices based on culture results.

PROGNOSIS

- Depends on etiology, duration and organism; usually poor, especially for traumatic cases.
- Correlation often seen with presenting visual acuity. The worse the patient's VA is upon presentation, the worse the prognosis.▼

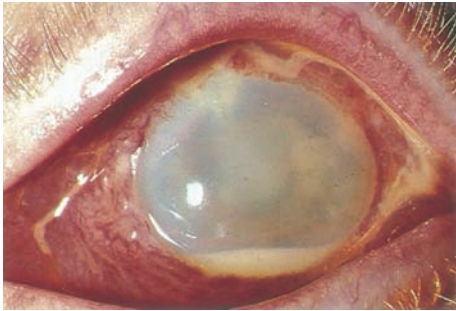

Fig. 15.1 Exogenous postoperative endophthalmitis (bacterial)

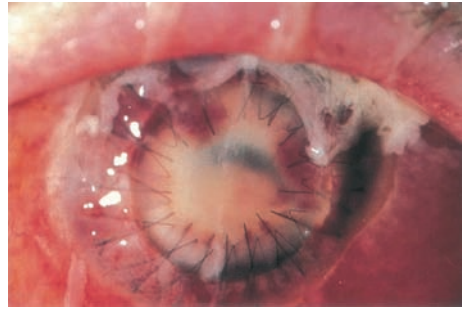


Fig. 15.2 Secure acute postoperative endophthalmitis caused by *Serratia marcescens*, following penetrating keratoplasty

Fig. 15.3
A and B, Chronic postoperative endophthalmitis caused by *P. acnes*. Note granulomatous keratic precipitates and white plaque in the capsular bag

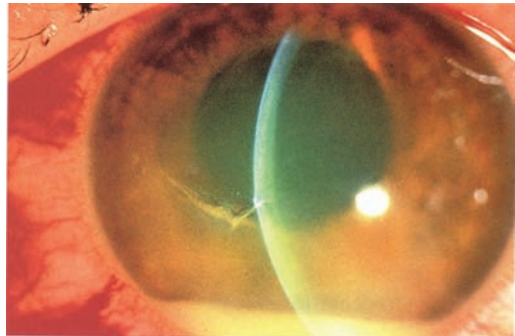
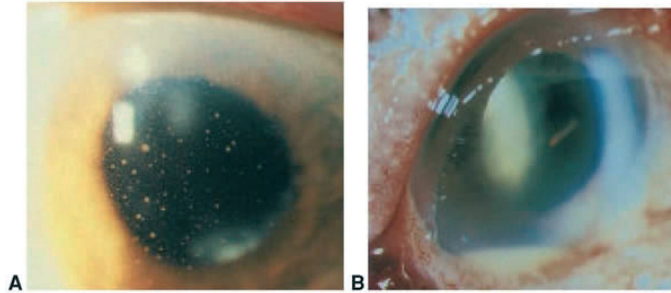


Fig. 15.4 Posttraumatic endophthalmitis

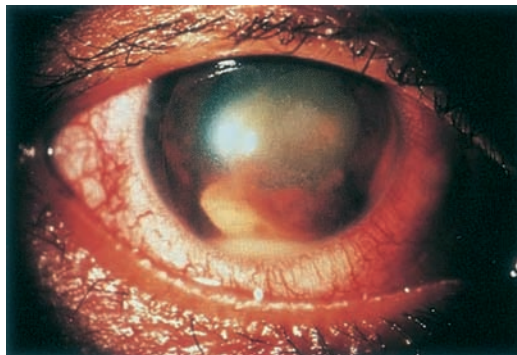


Fig. 15.5 Fungal endophthalmitis



16. POSTOPERATIVE CONSIDERATIONS

Postoperative care should be directed towards maintaining a clean and healthy post-op. eye. Healing and visual rehabilitation usually requires 4 to 5 weeks.

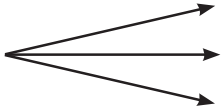
Although serious postoperative complications are not common, the ophthalmologists must be able to recognize them and immediately initiate an appropriate treatment or refer a patient to the surgeon.

Endophthalmitis falls into two categories: immediate, and late. Immediate endophthalmitis occurs within one or two days of ocular surgery and is more virulent and more rapidly progressing, than late endophthalmitis, most often due to *Staph. aureus* or possibly *pseudomonas*. Late endophthalmitis usually happens within four to ten days and is most often due to *Staph epidermidis* (the most common type of endophthalmitis) or *pseudomonas*. Still later cases may be found of fungal endophthalmitis occurring many weeks after the surgery.

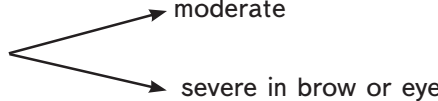
Salvaging an eye with endophthalmitis will usually depend on early diagnosis. Too often an eye with endophthalmitis is too far infected to recover. Early diagnosis and treatment is essential. Endophthalmitis should be considered in ALL p/o patients who have pain in the eye or a foreign body sensation after ocular surgery. The following are the signs and symptoms of this disorder. Any of them should alert the practitioner to recheck the patient.

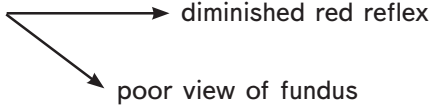
Sudden onset of progressively decreasing vision, redness and increasing eye pain.

SIGNS

- + 1. Vision: 
- decreasing vision
 - significantly decreasing vision
 - near loss of vision

Additional signs and symptoms possible:

- ± 2. Erythema and edema of lid
- ± 3. Discharge purulent on the ocular surface
- ± 4. Conjunctival swelling (chemosis)
- ± 5. Injection
- ± 6. Pain 
 - moderate
 - severe in brow or eye
- ± 7. Cells and flare within the anterior chamber, hypopion possible
- + 8. Slow pupil reaction

This is difficult to gauge as the patient has p/o dilation from anesthesia.
- + 9. Light sensitivity marked or progressive
- + 10. Fundus exam:: 
 - diminished red reflex
 - poor view of fundus

Emergency referral necessary to a retinal surgeon if possible for intravitreal injections of antibiotics.

SYMPTOMS

1. Decreasing vision or loss of vision
2. Conjunctival swelling (chemosis) and red eye
3. Pain – moderate in brow or eye

SIGNS

1. Hypopion possible
2. Reduced red reflex, poor view of posterior pole by ophthalmoscopy
3. Erythema and edema of lid
4. Discharge purulent on the ocular face

IF THE PATIENT IN THE POST-OP PERIOD DEVELOPS:

- ! Severe pain
- ! Nausea or vomiting
- ! Severe swelling around the eye

IMMEDIATE TREATMENT IS NEEDED:

1. Warm compresses
2. Antibiotic drops – each hour: Ciprofloxacin 0.3 % or Moxicin 0.5 % or Tobramycin 0.3 %
May require steroid drops after loading dose of antibiotics to prevent scarring
After glaucoma surgery if a patient has a painful eye, IOP is elevated and a shallow anterior chamber is not present prescribe:
After ocular surgery if patient has painful eye, look for Fluorescein leak (Seidel positive). If positive Seidel, if several days p/o return to OR. If day of surgery, patch eye and reduce steroid drops.
If negative Seidel, and pressure is high consider p/o Glaucoma and treat as below

1. warm compresses Q1H
2. antibiotic drops (ciprofloxacin 0.3 % or Moxicin 0.5 % or Tobramycin) QID
3. Diamox 500 mg. oral BID depending upon pressure spike
4. Emergency release of AC fluid from paracentesis wound if pressure > 50

1. Warm compresses
2. Antibiotic drops (ciprofloxacin 0.3 % or Moxicin 0.5 % or Tobramycin) each hour
3. Timolol 1/2% BID
4. Trusopt BID
5. Xalatan QHS
6. Alphagan BID
7. Consider performing anterior chamber paracentesis in case of high intraocular pressure (IOP > 50 mm Hg)

POSTOPERATIVE CARE

Postoperative Care depends upon which method of surgery was chosen.

1. With ICCE or ECCE resulting in a large wound, healing occurs slowly over a 6- to 8-week period, but refractive changes due to further healing of the incision occur up to 9 mo. postoperatively. Non-absorbable sutures may be cut or removed if protruding or inducing astigmatism usually between 6 and 8 weeks; some are not removed. Phako or small incision sutureless ECCE wounds heal in one month. Patients can usually return to full activities within two weeks.
2. Postoperative medications usually include an antibiotic and steroid combination, which is continued for several weeks at the discretion of the surgeon, e.g. Pred-Forte, Inflammase Forte or Maxitrol. It is better to keep the regime simple. The suggested regime is Steroid drops and Antibiotic drops (Ciloxan, Ocuflax, Zymer, Vigamox) 4 times a day (or 8 times a day if a long case) continuing for three weeks (or longer if a difficult case). They may be tapered off slowly over several weeks and are preferable to incorporating the use of

FML. b.i.d.- q.i.d. 2-3 weeks and then a mild steroid (FML) qd for 3-4- weeks.

3. Restrictions on activity depend on the size of the incision and also should be individualized to the particular patient.
4. General medical considerations.
Constipation, coughing and sneezing should be avoided.

Anticoagulant therapy should be delayed for at least a few weeks. This is more dependent upon the method of anesthesia. Peribulbar anesthesia is most commonly used now, while retrobulbar anesthesia has not been done for years. Topical anesthesia is often done. Neither Topical nor Peribulbar anesthesia requires patients to discontinue their anticoagulants.

5. Follow-up appointments should generally occur at 1 day, 1 week, 3 weeks, and 6 weeks postoperatively, but also should be tailored to the particular setting. In case of an uneventful clear corneal phacoemulsification follow-up appointments should occur at 1 day and 3 weeks postoperatively.

POSTOPERATIVE COMPLICATIONS

1. Cystoid Macular Edema (CME) (**Chapter 9. 5**)
2. Endophthalmitis (**Chapter 15**)
3. Posterior Capsular Opacification (PCO) (**Chapter 5. 12**) ▼



17. BLIND, PAINFUL EYE

A painful eye that has no light perception and no chance for visual rehabilitation. Pain is usually from elevated IOP but may also be due to inflammation and surface breakdown.

ETIOLOGY

Perforating corneal ulcer, retinal detachment, uveitis, multiple surgical procedures, end-stage primary glaucoma, neovascular glaucoma.

MANAGEMENT

Complete ocular examination including fluorescein staining of cornea; IOP should be measured only if no epithelial corneal defects are present, and fundus examination should be conducted, if possible.

If the cornea is not opacified, obstructing visualization, examine anterior segment to evaluate the presence of neovascularization of the iris and anterior chamber reaction.

TREATMENT

Steroid drops - Prednisolone acetate 1% qid and atropine 1% bid.

If a large corneal epithelial defect is present, a topical antibiotic and cycloplegic should be used. Aggressive lubrication and tarsorrhphy are considered*.

Standard glaucoma medication may be used for IOP control but

are not necessary if pain and cornea status are improved, even in presence of high pressure.

WARNING: NEVER use Pilocarpine in patients with neovascular glaucoma, since it causes an inflammation and accelerates the pain.

If elevated IOP is not controlled with topical medications and pain persists, cyclophotocoagulation of the ciliary body may be performed to lower the IOP.

Neovascular glaucoma may require a glaucoma drainage implant (Ahmed valve).

Retrolubar injection of alcohol is other option.

Enucleation is offered as a final option.

* lubrication with lubricants, artificial tears. ▼



18. OCULAR PHARMACOLOGY

ANTIBIOTICS CEFALOSPORINS

1st generation: cefazolin (Kefzol), cephalixin (Keflex)

Spectrum: Gram-positive and some Gram-negative

Indications: cefazolin for keratitis, endophthalmitis

2nd generation: cefuroxime (Zinacef)

Spectrum: better Gram-negative but less Gram-positive activity, Haemophilus influenzae and Neisseria

3rd generation: cefotaxime (Claforan), ceftazidime (Ceftazidime), ceftriaxone (Rocephin)

Spectrum: even better Gram-negative, Pseudomonas (Ceftazidime)

FLUOROQUINOLONES

2nd generation (gen.): ciprofloxacin, ofloxacin, norfloxacin - available as a 0.3% eye drops solution, Norfloxacin is also available as an eye ointment.

3rd gen: levofloxacin 0.5% solution

4th gen: gatifloxacin (Zymar), moxifloxacin (Vigamox, also Moxicin (the trade name of the Armenian product of Liquor pharmaceutical company)) 0.5% solution.

Spectrum: aerobic Gram-negative and some Gram+. 4th gen. agents have extended spectrum with enhanced activity against Gram+, fluoroquinolone-resistant organisms, and atypical mycobacteria.

Indications: conjunctivitis, keratitis, surgical prophylaxis; prophylaxis in penetrating trauma (oral cipro achieves high levels in vitreous)

Adverse effects: GI upset; cartilage damage in children

POINTS TO REMEMBER:

TO PREVENT RESISTANCE IN FLUOROQUINOLONES ALWAYS PRESCRIBE NO LESS THAN qid - 4 times a day for topical use.

ANTIVIRALS

Topical: treatment of HSV keratitis

Idoxuridine (IDU) - production is discontinued due to corneal toxicity - corneal epithelopathy.

Vidarabine: adverse effects less severe than IDU - not available in Armenia

Trifluorothymidine (Viroptic), best tolerated - not available in Armenia

ACYCLOVIR for topical and systemic usage

Acyclovir (Zovirax) 3% ocular ointment is available and registered in Armenia

Tabs 200 mg or 800 mg

Valacyclovir (Valtrex; prodrug of acyclovir) is also available.

ANTI-INFLAMMATORY DRUGS

Nonsteroidal Anti-inflammatory Drugs (NSAIDs)

Acetic acids: indomethacin, diclofenac (Voltaren), ketorolac (Acular) Flurbiprofen (Ocufen)

Indications:

Prevent myosis during intraocular surgery: Profenal, Ocufen
 Allergic conj., corneal pain, postsurgical inflammation, CME: Voltaren, Acular

Steroids

For topical use

Prednisolone acetate 1%

Dexamethasone phosphate 0.1%

Dexamethasone alcohol 0.1% (Maxidex)

Steroids with less IOP elevating potential: fluoromethalone (FML), rimexolone (Vexol), loteprednol (Lotemax, ALrex)

For injections: subtenons, retrobulbar, intravitreal
 Triamcinolone acetonide (Kenalog)

For subconjunctival, periocular injections:

Betamethasone (Celeston)

Indications:conjunctivitis, keratitis, scleritis, uveitis, hyphema, CME, endophthalmitis

Adverse ocular effects:

cataracts, elevated IOP, delayed wound healing/ corneal re-epithelization, secondary infections

POINTS TO REMEMBER:

TOPICAL STEROIDS ARE CONTRAINDICATED IN HERPETIC DENDRITIC KERATITIS

ANTIALLERGY MEDICATIONS

Antihistamines /Vasoconstrictors

Naphazoline/pheniramine maleate (Naphcon-A)

Naphazoline/antazoline phosphate (Vasocon-A)

Vasoconstrictor naphazoline temporarily removes redness, but can cause redness with chronic use.

Mast Cell Stabilizer

Cromolyn (Crolom; Optocrom, Lecrolin, Chromohexal- is useful for chronic allergies, not for acute symptomatic relief

H1- Blockers + Mast Cell Stabilizer + NSAID

Nedocromil (ALOCRIL), Ketotifen (Zaditor): triple -action drugs are effective against itching, but less for redness

Mast Cell Stabilizer, Eosinophil Suppressor

Lodoxamide (Alomide)

H1- blockers (antihistamines)

Emedastine (Emadine) bind to histamine receptors (inhibits itching and hyperemia)

H1-Blocker + Mast Cell Stabilizer

Olopatadine (Patanol)

OCULAR HYPOTENSIVE (GLAUCOMA) MEDICATIONS**PROSTAGLANDIN ANALOGUES**

Mechanism: increase uveoscleral outflow

Latanoprost (Xalatan), travoprost (Travatan), bimatoprost (Lumigan), unoprostone (Rescula)

Adverse effects: flu-like symptoms, hyperemia, eyelash growth, iris pigmentation (increase the number of melanosomes), CME, reactivation of HSV keratitis

Contraindications; pseudophakia (causes CME), uveitis (increase the inflammation)

β-BLOCKERS

Mechanism: reduce aqueous production

NONSELECTIVE (β₁ and β₂): timolol (Timoptic), levobunolol (Betagan), metipranolol (Optipranolol), carteolol (Ocupress)

CARDIOSELECTIVE : betaxolol (Betoptic)

Fewer pulmonary adverse effects

Indications: patients with pulmonary problems who cannot tolerate nonselective β -blocker; often used for normal tension glaucoma; may not cause as much vasoconstriction of vessels supplying optic nerve.

α_2 -AGONISTS

Apraclonidine (Iopidine), brimonidine (Alphagan -P)

Mechanism: reduce aqueous production

Adverse effects: allergy, superior lid retraction, dry mouth, blanching of conjunctival vessels, miosis, lethargy, headache

MIOTICS

Mechanism: increase aqueous outflow (contraction of ciliary muscle opens trabecular meshwork), decrease uveoscleral outflow.

Pilocarpine: acetylcholine agonist; peak action at 2 hours, 8-hour duration

Beware of treatment for angle-closure: causes shallowing of AC and narrowing of angle, but miosis pulls peripheral iris away from angle, balancing out the other effects

Adverse effects: headache, accommodative spasm, miosis (dimming, reduction of vision) myopia (forward shift of lens-iris diaphragm), pupillary block, follicular conjunctivitis, dermatitis, rarely retinal tear.

POINTS TO REMEMBER:

FOR INITIAL TREATMENT OF ACUTE ATTACK OF ANGLE CLOSURE GLAUCOMA INSTILL Pilocarpine 1%-2% q. 15 minutes ONLY 3 TIMES

CARBONIC ANHYDRASE INHIBITORS

Mechanism: decrease bicarbonate formation in ciliary body epithelium
- reduce aqueous production.

POINTS TO REMEMBER:

WARNING: Do not administer to patients with sulfa allergy, since carbonic anhydrase inhibitors are sulfonamide derivatives.

Oral: acetazolamide (Diamox, PO) IV solution is not available in Armenia, methazolamide (Neptazane; PO; more lipid soluble, less toxicity)

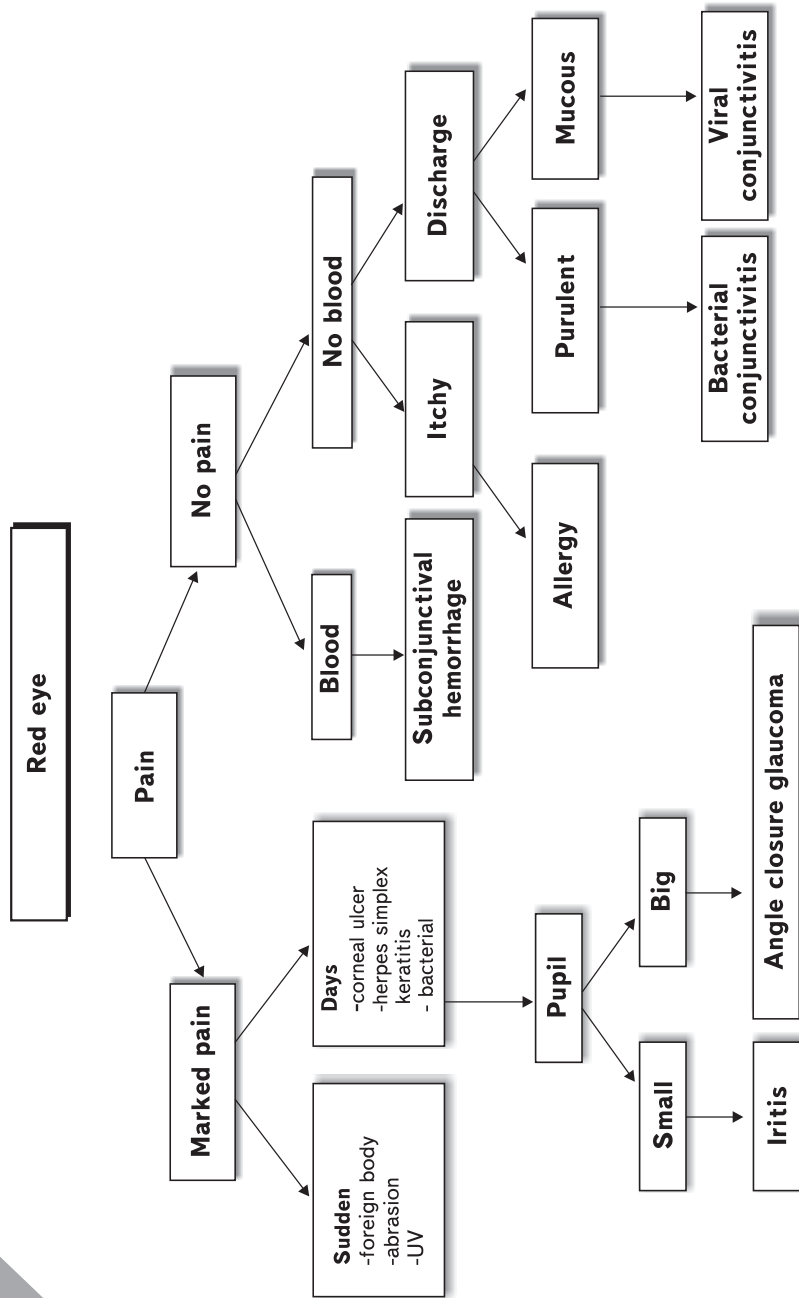
Topical: dorzolamide (Trusopt), brinzolamide (Azopt)

Adverse effects: metallic taste, paresthesias, malaise, weight loss, depression, skin rash, corneal edema.

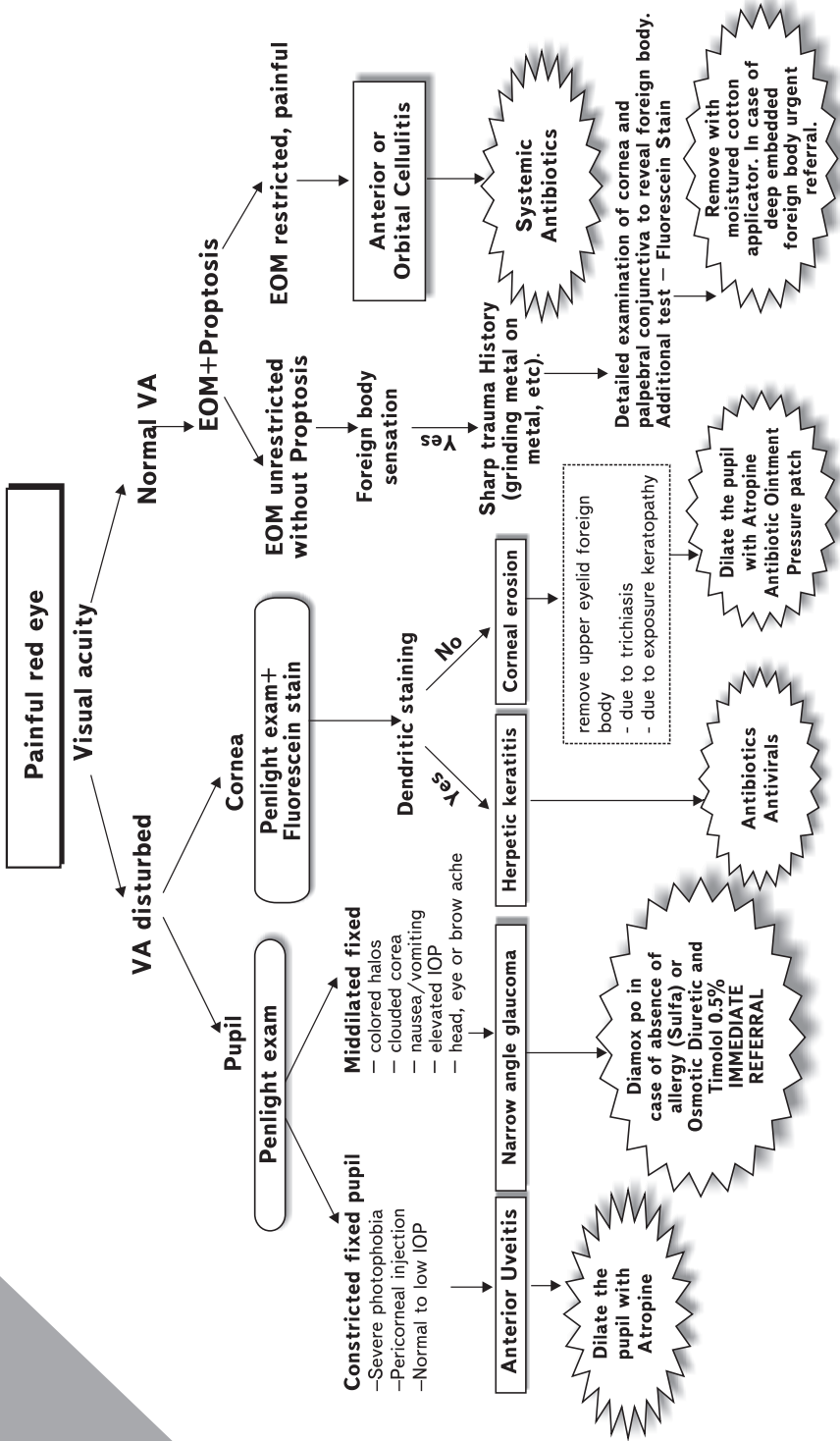
Combined eye drops: Maxitrol (Alcon) combination of Dexamethasone alcohol 0.1% with Neomycin and Polymixin B ▼


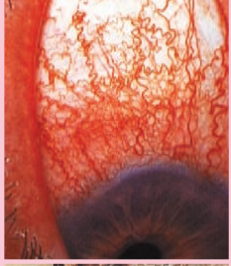
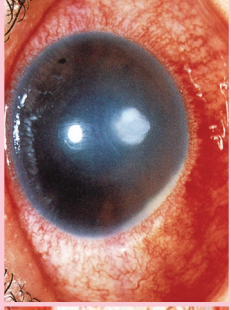

19. DIAGNOSTIC FLOW SHEETS

PAINFUL AND PAINLESS RED EYE

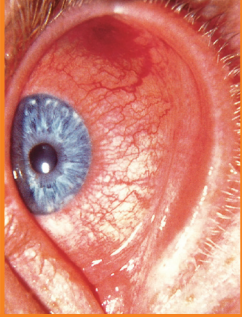




RED EYE WITH AND WITHOUT VISION LOSS



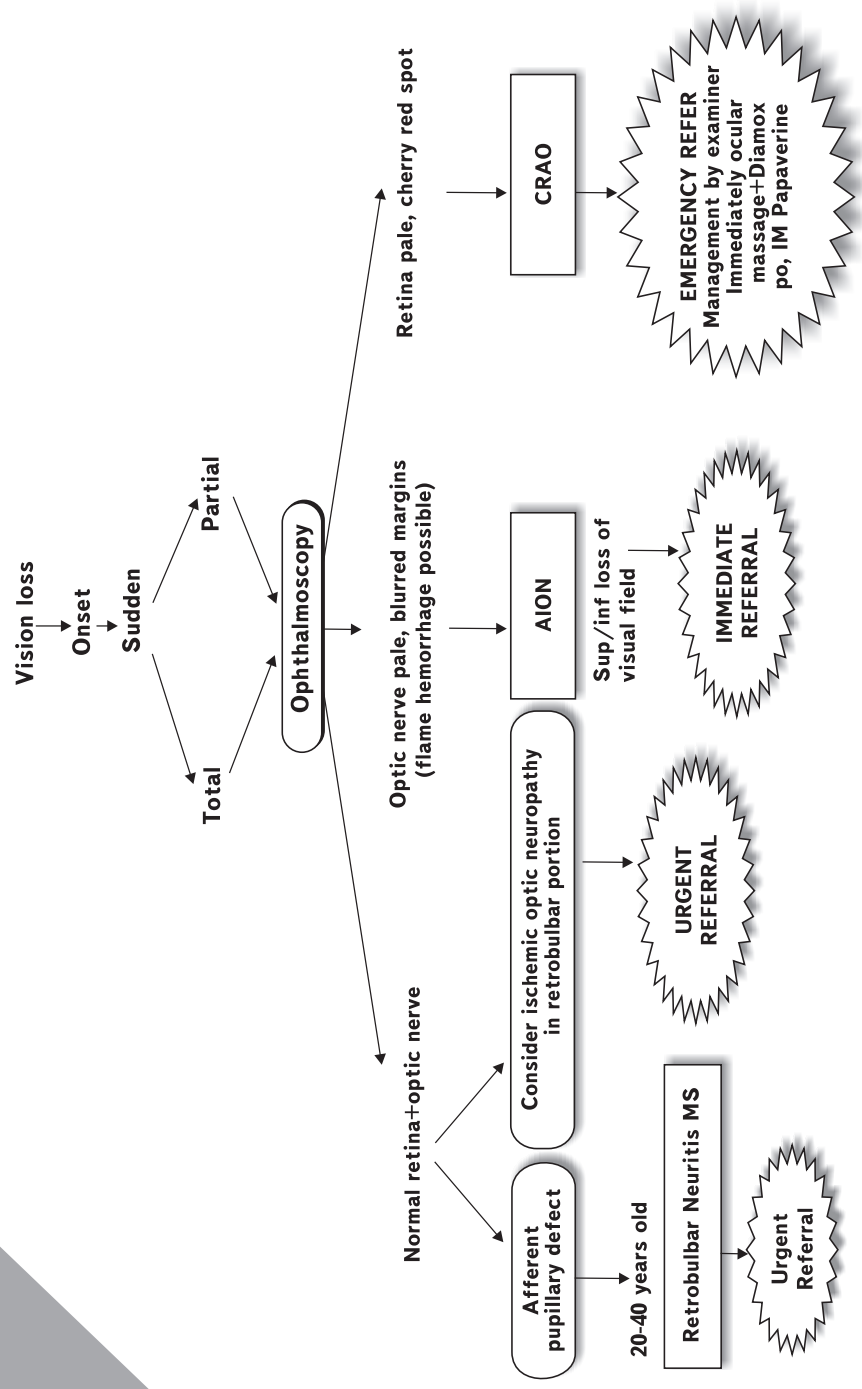
Signs	Diagnosis	Conjunctivitis	Iritis	Keratitis (corneal inflammation or foreign body)	Acute Glaucoma
Vision		Normal or intermittent blurring that clears on blinking	Slightly blurred	Marked blurring	Marked blurring
Discharge		Usually significant with crusting of lashes	None	None to mild	None
Pain		None or minor and superficial	Moderately severe, aching and photophobia	Sharp, severe foreign body sensation	Very severe head, brow or eyeache, frequent nausea and vomiting
Pupil size		Normal	Constricted	Normal or constricted	Dilated
Conjunctiva; injection		Diffuse	Circum corneal	Circum corneal	Diffuse with prominent circum corneal injection
Pupillary response to light		Normal	Minimal further constriction	Normal	Minimal or no reaction of dilated pupil
Intraocular pressure		Normal Caution: After measurement clean the instrument thoroughly	Normal to low	Normal Caution: Do not measure	Elevated
Appearance of cornea		Clear	Clear or slightly hazy	Opacification present: altered light reflex; positive fluorescein staining	Hazy, altered light reflex Poor iris details compared with opposite eye
Anterior chamber depth		Normal	Normal	Normal	Shallow
DIAGNOSIS					
MANAGEMENT		Antibiotic drops (0.3% Gentamycin 4 times a day) and ointment (Erythromycin or Gentamycin) at bedtime for 5 days	Dilate the pupil with Atropine 1% 2x daily Steroids topically, if not responding then periocular injections, in severe cases systemic steroids	In case of keratitis or corneal ulcer Antibiotics+Antivirals	Timolol 0.5% and Pilocarpine 1-2% 3 times each 15 min. Diamox 250mg per os in case of absence of allergy (sulfa) or osmotic diuretic

DIFFERENTIAL DIAGNOSIS OF CONJUNCTIVITIS

Ethiology	Viral	Bacterial Purulent	Allergy
DIAGNOSIS			
Discharge	Minimal	Copious	Minimal
Tearing	Copious	Moderate	Moderate
Itching	Minimal	Minimal	Marked
Injection	General	General	General
Preauricular Node	Common	Uncommon	-0-
Associated Sore Throat and Fever	Occasional	Seldom	-0-
DIAGNOSIS			

19.5

ACUTE VISION LOSS

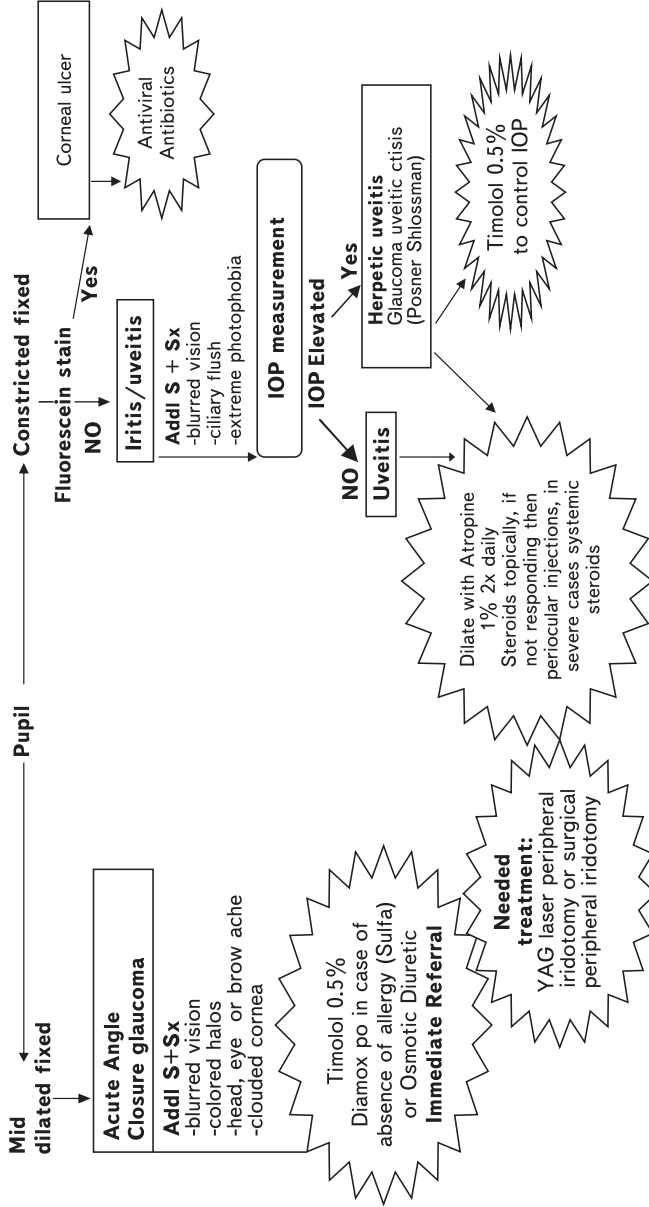


GRADUAL VISION LOSS OVER HOURS TO DAY

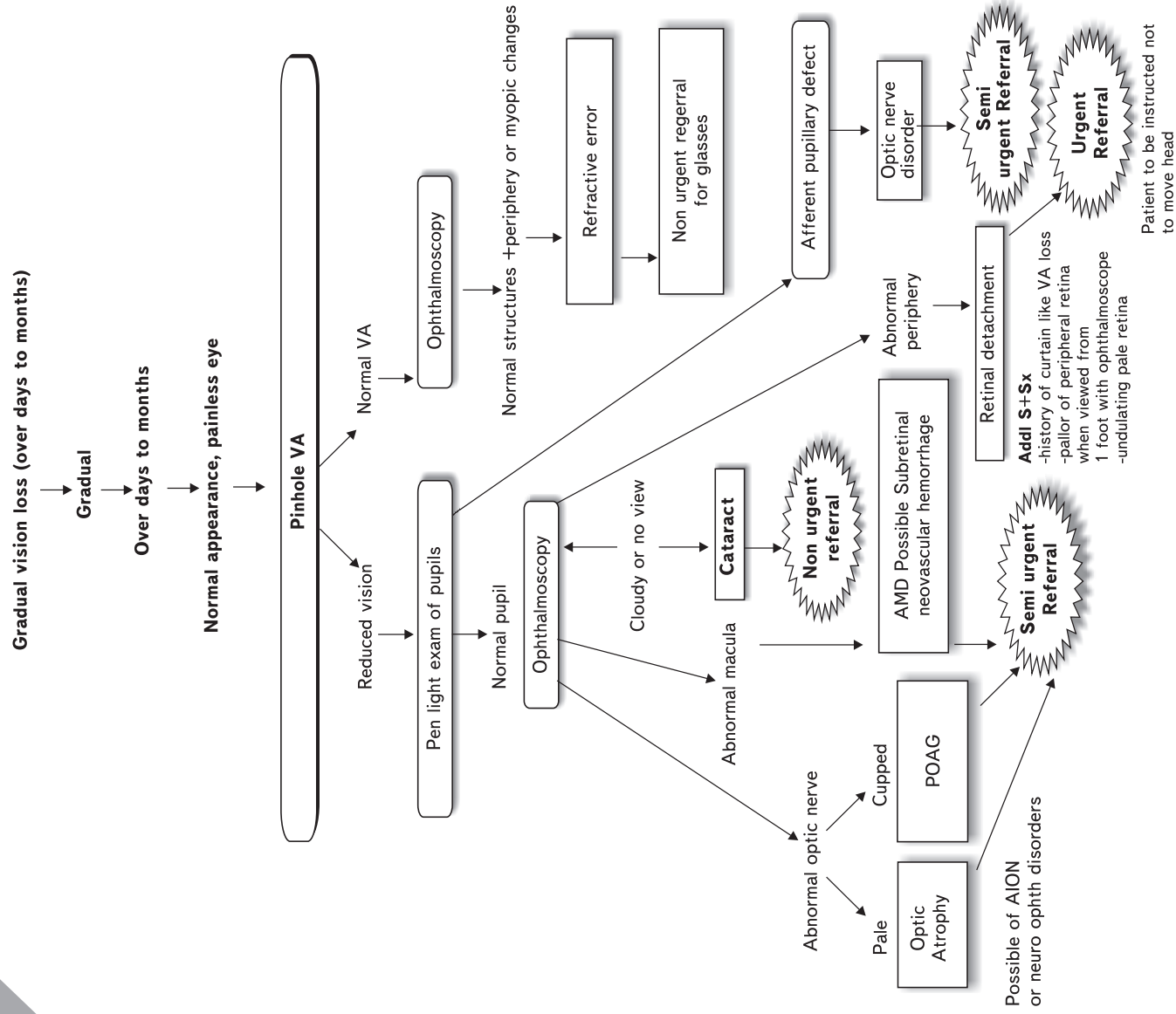
Gradual vision loss ← Over hours to day

Red eye + painful usually

Pen light exam



GRADUAL VISION LOSS OVER DAYS TO MONTHS



19.8 VISION LOSS

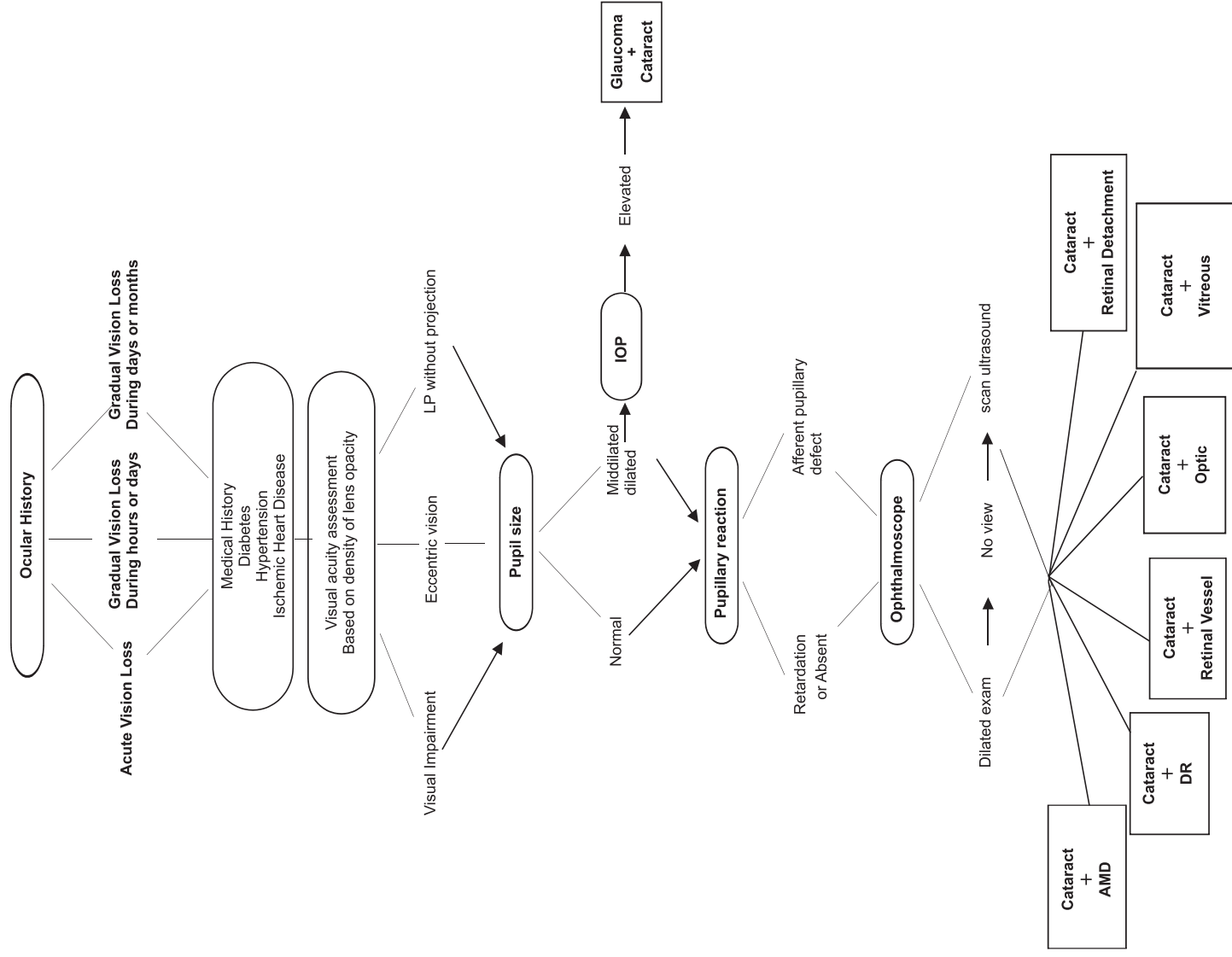
	Key symptoms	Associated conditions	Signs
Acute painless			
Vitreous hemorrhage*	Spider webs, floaters	DM, sickle cell, blood dyscrasias	Diminished red reflex
Retinal detachment*	Flashes, floaters	Nearsightedness, history of trauma	Reduced unilateral visual field
Retinal artery occlusion*	Amaurosis fugax	Embolic or carotid artery disease	Cherry red spot
Retinal vein occlusion*	HTN symptoms	HTN, blood dyscrasias	“blood and thunder” appearance
Exudates (wet) MD*	Metamorphopsia	Age over 60 years	Retinal hem in macula
Ischemic optic neuropathy*	Jaw, scalp, neck pain	Age over 60 years , temporal arteritis	Swollen optic nerve head
Cerebral infarct	Other neurologic signs	Vascular disease	Homonymous visual field defect

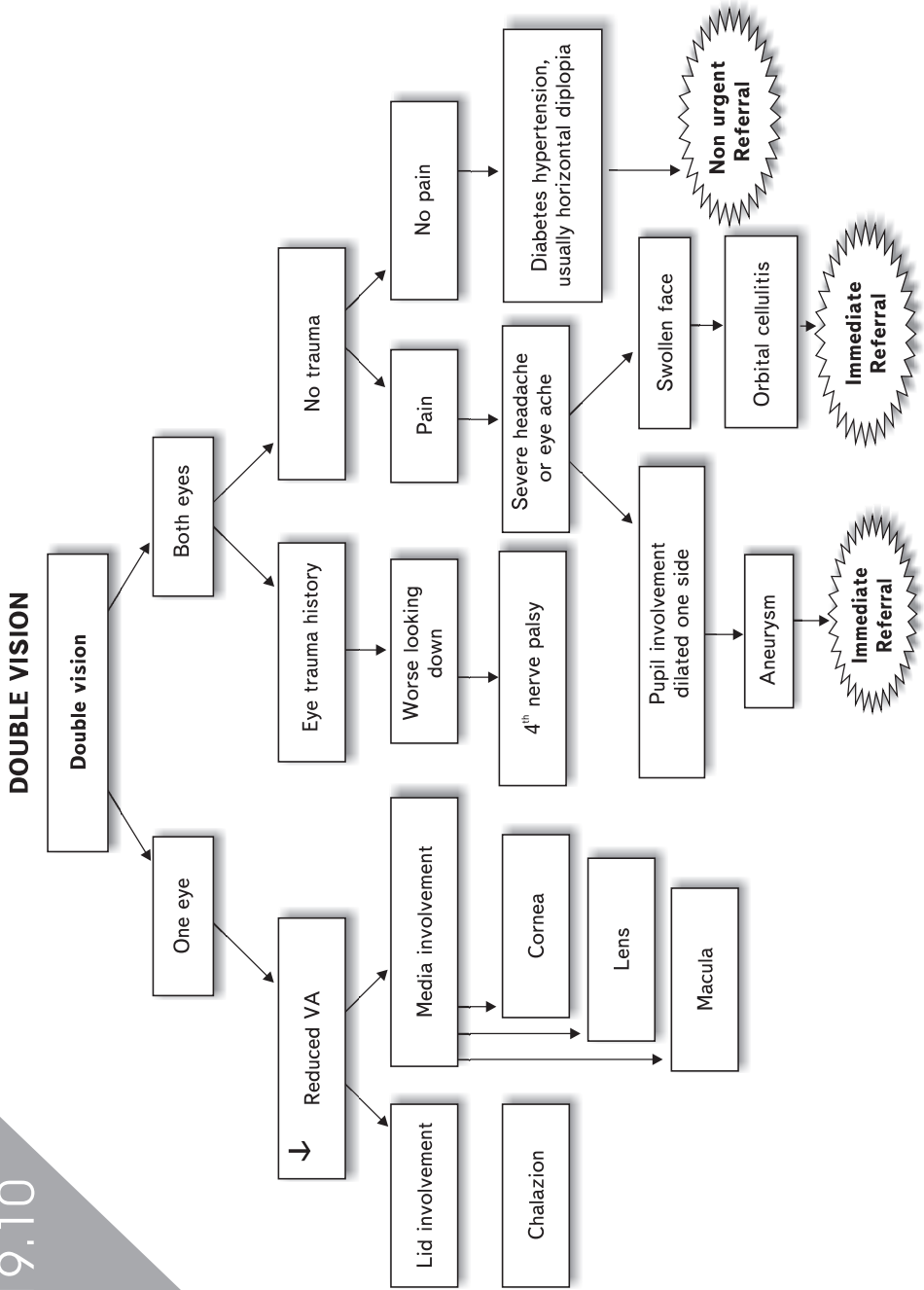
	Key symptoms	Associated conditions	Signs
Acute painful			
Corneal ulcer	Pain with extraocular movements or blinking	Trauma, contacts	Ulcer, hypopyon
Optic neuritis*	Pain increases or decreases with extraocular movement	Age 15-45 years, MS	Fundus or disc appears normal in two thirds of patients
Uveitis	History of sensitivity to light	Trauma, HLA-B27	Limbic flush, C & F
Angle -closure glaucoma	Retro-orbital headache, nausea and vomiting	Farsighted elderly	Mid-dilated pupil, hazy cornea
Endophthalmitis*	Fever, headache	Recent eye surgery	Mucopurulent discharge

	Key symptoms	Associated conditions	Signs
Chronic progressive			
Refractive error	Gradual	Glasses and contact lens wearers	Normal visual acuity with pinhole
Cataract	Multiple images	Family history, DM, steroid use	Cannot see fundus
Open angle glaucoma	Often none	Family history, DM, African-Americans	Cup to disc ratio greater than 0.6
Atrophic (dry) MD*	Central scotoma	Family history, age over 60 years	Drusen, scar formation
Diabetic retinopathy*	Gradual patchy decline	Poorly controlled DM	Neovascularization
Brain tumor	Neovascular, other neurologic		Papilledema if ICP is elevated

* may present with an afferent pupillary defect
DM=diabetes mellitus; MD=macular degeneration; HTN=hypertension; MS=multiple sclerosis; C&F= cell and flare; ICP=intracranial pressure

CO-EXISTING EYE DISEASE IN CATARACT PATIENTS





19. 11 SIGNS / SYMPTOMS OF COMPLICATIONS AFTER OCULAR SURGERY

	Risk Factors	Early Warning	Urgent Referral Necessary	Emergent Referral Necessary
Intraocular Pressure (IOP)	<ul style="list-style-type: none"> Previous glaucoma ✓ PEX ✓ Vitreous loss ✓ Retained nucleus/cortex 	<p>IOP 25 - 30 mmHg</p>	<p>IOP > 30 pt. ct.</p> <ul style="list-style-type: none"> ✓ Corneal epithelial edema ✓ Hazy view of AC <p>Rx: drops</p>	<p>IOP > 40 despite treatment with drops</p> <ul style="list-style-type: none"> ✓ Corneal “wall to wall” edema +bullae <p>Rx:drops+poss AC tap</p>
Endophthalmitis:	<ul style="list-style-type: none"> ✓ Surgery 2-4 days previously ✓ Vitreous loss ✓ Complicated or prolonged surgical procedure ✓ Diabetic ✓ Immunocompromised ✓ loose suture/ + Seidel 	<ul style="list-style-type: none"> ✓ Decreasing vision ✓ Photophobia ✓ Significant pain in brow or eye ✓ Slow pupil reaction ✓ Diminished red reflex ✓ Nausea 	<p>→→→</p>	<ul style="list-style-type: none"> ✓ Hypopyon ✓ Near loss of vision ✓ Poor view of fundus <p>Rx: intravitreal tap and antibiotic injections</p>

	Risk Factors	Early Warning	Urgent Referral Necessary	Emergent Referral Necessary
Orbital infection or hemorrhage	<ul style="list-style-type: none"> ✓ Diabetes ✓ Open or dirty wound ✓ Recent orbital trauma ✓ Strabismus or eyelid surgery ✓ Coagulopathy or blood thinners 	<ul style="list-style-type: none"> ✓ Erythema and edema of lid ✓ Tenderness/pain ✓ Fever 		<ul style="list-style-type: none"> ✓ Tense ecchymosis/subconjunctival hemorrhage ✓ Significant pain or purulent discharge

See your doctor without delay if the following symptoms occur after surgery:

- ✓ Sudden vision loss
- ✓ Severe pain
- ✓ Nausea or vomiting
- ✓ Severe swelling around the eye



APPENDIX:

CLINICAL SKILLS

ADMINISTERING EYEDROPS AND OINTMENTS

1. Have the patient sit or lie down.
2. Wash your hands thoroughly.
3. Check the physician's instructions - what medication and which eye?
4. Select the correct medication and check the expiration date. Always read the label. Many ophthalmic medication bottles look alike.
5. If the medication to be used is a suspension, shake the container well to ensure the drug is distributed consistently throughout the liquid.
6. To maintain sterility of the bottle contents, do not allow the inside edge of the bottle cap to contact any surface or object other than the bottle. Avoid touching the bottle tip to the lids, lashes, or surface of the eye.

Instilling Eyedrops

Improperly instilled eyedrops do not reach the eye. The following technique helps ensure optimal drug delivery.

1. Have the patient recline or tilt the head far back. If patient has difficulty bending the neck back, have him or her recline in the exam chair.
2. Ask the patient to look up, with both eyes open.
3. Use the little finger or ring finger of the hand holding the bottle to gently pull down the skin over the cheekbone, pulling the lower lid down and out. This motion exposes the conjunctival cul-de-sac, creating a cup to catch the drops.

4. Squeeze the bottle gently to expel a drop of medication. Try to direct the drop toward the sensitive surface of the cornea (Figure 1).
5. Instruct the patient to close both eyes gently. Use your index finger to apply light pressure over the lacrimal sac for 15-30seconds (Figure 2). These actions help prevent systemic absorption by reducing the amount of the drug that drains into the lacrimal system nose, and throat.
6. Wipe any excess drops from the patient's lids with a clean tissue.
7. Record the following information in the patient's chart:
 - a. Medication name and strength
 - b. Time administered
 - c. Which eye received the medication.

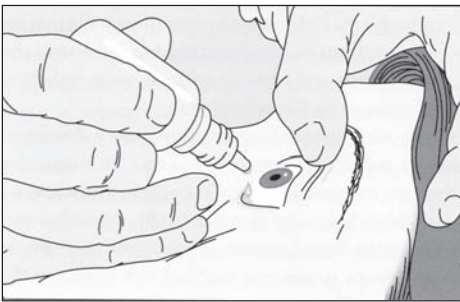


Fig. 1

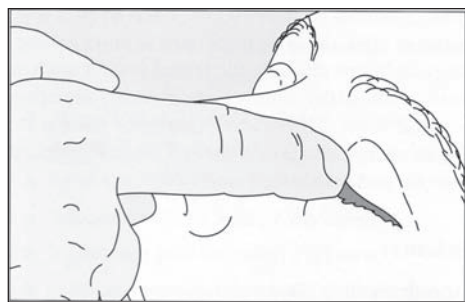


Fig. 2

Applying Ointments

Perform steps 1 through 6 of the section “Preliminaries” earlier in this box. Then continue with steps 1 through 5 below.

1. If the tube of ointment has been opened prior to this use, express 1 inch of ointment onto a fresh cotton ball, gauze, or tissue and discard it.
2. Squeezing the tube lightly and with even pressure, apply the ointment along the conjunctival surface of the lower lid, moving from the inner to the outer canthus (Figure 3). Usually 1/2 to 1 inch of ointment is enough. Avoid touching the tip of the tube to the eye, eyelashes, or skin to prevent contamination of the ointment tube. With a twisting motion, detach the ointment from the tip of the container.
3. Instruct the patient to close the eyes gently.

4. Wipe any excess ointment from the skin with a fresh cotton ball, gauze, or tissue; then discard it properly.
5. Record the application of ointment in the patient chart, as described in step 7 under “Instilling Eyedrops” above.

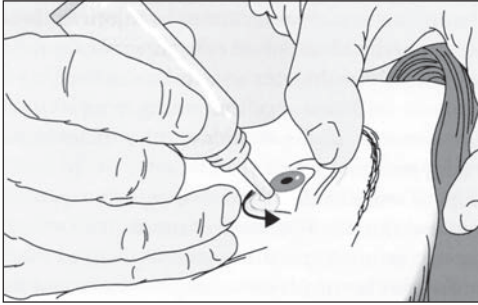


Fig. 3

IRRIGATING THE EYE

1. Immediately upon arrival, ask the patient to lie down on a stretcher, sofa, examining table, or a chair with a tilted back.
2. If the ophthalmologist requires and permits and if the patient has no known allergy to anesthetic medication instill one drop of topical anesthetic solution. (Information about instilling eyedrops appears in Chapter 11, “Basics of Ophthalmic Pharmacology.”)
3. Holding a gauze pad to help you keep your grasp, use your gloved fingers to separate the lids of the affected eye. Gently but firmly hold the lids open to counter the spasm and forceful closure of the eye during irrigation. A lid speculum may also be used to hold the lids open.
4. Give the patient a towel to hold against the face to absorb the excess fluid. In addition, you can position a basin next to the patient's face to catch the fluid.
5. Perform irrigation with a bottle of readymade balanced salt solution **IF not available, them use ANY available water source**. If available, a continuous-rapid-drip bottle (suspended like an intravenous drip) is easier because you don't have to keep squeezing the bottle; you just have to direct the stream into the patient's eye. Direct the irrigating stream away from the nose to avoid contaminating the other eye. (Fig. 4, 5)
6. You may need to evert (turn out) the upper lid while irrigating to wash away particles of chemical that may have become lodged there. To evert the lid:
 - a. With the thumb and forefinger of one gloved hand, grasp the

lashes of the upper lid and pull it out and down slightly (Figure A).

b. Using your other hand, place the stick portion of a cotton-tipped applicator horizontally on the upper eyelid, approximately 5 mm above the margin of the eyelid (Figure B).

c. Rotate the lid up and over the applicator stick to expose the conjunctival surface (Figure C).

7. After irrigation has been completed, patch the eye if you have been requested to do so.

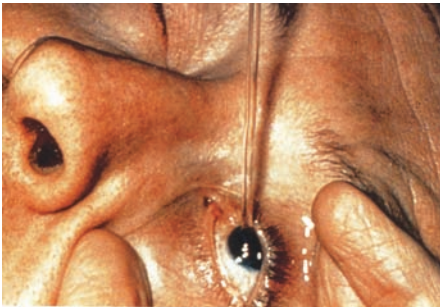

Fig. 4 Eye irrigation (first option)

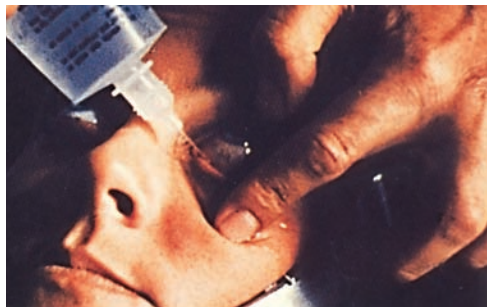

Fig. 5 Eye irrigation (second option)

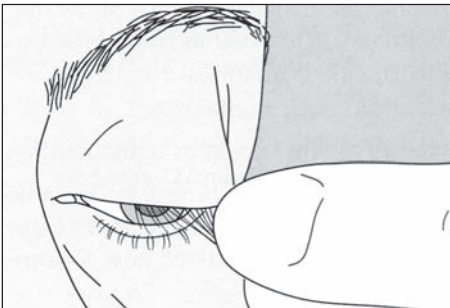

Fig. A With the thumb and forefinger of one gloved hand, grasp the lashes of the upper lid and pull it out and down slightly

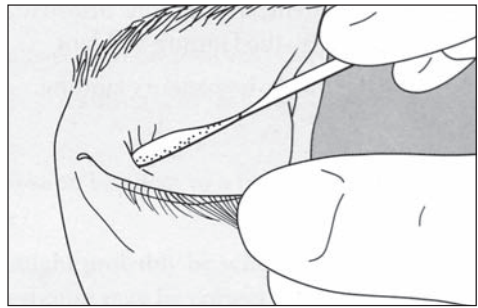


Fig. B Using your other hand, place the stick portion of a cotton-tipped applicator horizontally on the upper eyelid, approximately 5 mm above the margin of the eyelid

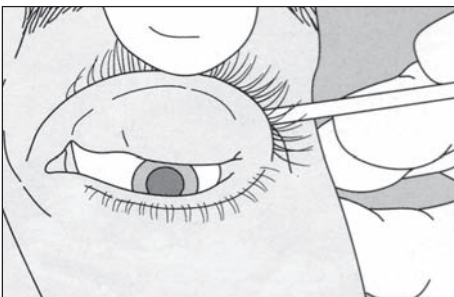


Fig. C Rotate the lid up and over the applicator stick to expose the conjunctival surface

APPLYING PRESSURE PATCHES AND SHIELDS

1. Set out two sterile eye pads and adhesive surgical tape. Tear the tape into 5-to 6-inch lengths to facilitate the patching process.
2. Instruct the patient to close both eyes tightly.
3. Clean the forehead and the area around the cheekbone and toward the ear with an alcohol pad to remove the skin oils. This helps the tape stick to the skin.
4. Fold one pad in half, place it over the closed eye, and hold it in place with one hand.
5. Apply an unfolded eye pad over the folded one.
6. Tape the unfolded eye pad firmly to the forehead and cheekbone (Figure 6). To prevent blinking, further bleeding, or swelling, the patch must exert some pressure on the lids. The patient should not be able to open the eyelid beneath the patch. The tape should not extend to the jawbone because jaw movement could loosen the patch.

! If the patient has any contusion or laceration of the globe or its adnexal structures, apply and tape a fenestrated aluminum (Fox) shield, instead of a pressure patch, over the globe, to protect these tissues from further damage until healing occurs or definitive repair is performed. Rest the shield on the bony eyebrow and cheekbone (Figure 7). Do not patch an open globe tightly. ▼

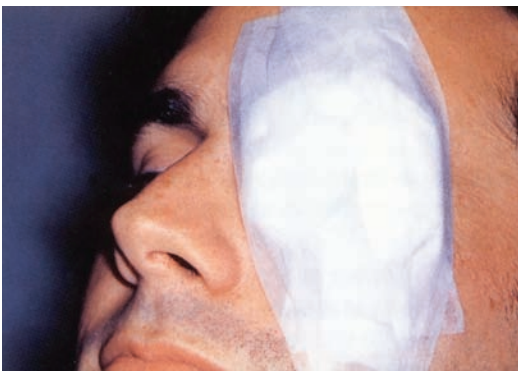

Fig. 6 Pressure patch

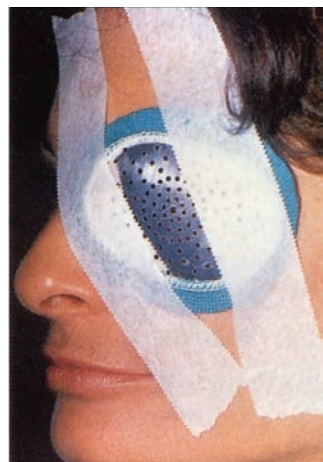

Fig.7 Shield


INDEX**A**

- Acquired uveitis **47-62**
- Acquired cataract **68-86**
- Acquired macula disorders
 - Age-related macular degeneration (AMD) **111**
 - Central serous retinopathy **117**
 - Cystoid Macular Edema (CME) **120**
- Acute angle closure glaucoma **148, 177**
- Afferent pupillary defect **14**
- Age-related macular degeneration (AMD) **111**
 - Nonexudative (dry) AMD **113**
 - Exudative (wet) AMD **114**
- Allergic conjunctivitis **26**
- Amblyopia **166**
- AMD (Age-related macular degeneration) **111**
- Amsler grid test **13**
- Angle closure glaucoma **148, 177**
- Anterior ischemic optic neuropathy **95**
- Anti-allergic treatment **197**
- Antibiotic therapy **195**
- Anti-inflammatory treatment **197**
 - Corticosteroids
 - Non-steroidal anti-inflammatory drugs **196**

B

- Bacterial keratitis **37**
- Behcet's disease **59**
- Blepharitis **17**
- Branch retinal artery occlusion (BRAO) **99**
- Branch retinal vein occlusion (BRVO) **107**

C

- Cataract
 - Congenital **65**
 - Acquired **65**
 - Age-related **68**
 - Drug-induced, toxic **68**
 - Management and treatment **74**
 - Cataract surgery timing **75**
 - Risks and complications **84**

- Cataract surgery **78**
- Anesthesia for cataract surgery **78**
- Cataract surgery techniques **81**
- Postoperative Care **83**
- Postoperative Complications **84**
- Cellulitis
 - Preseptal cellulitis **20**
 - Orbital Cellulitis **22**
- Central retinal artery occlusion (CRAO) **99,173**
- Central retinal vein occlusion (CRVO) **102**
- Central serous retinopathy **117**
- Chemical burns **117**
- Convergent strabismus **158**
- Confrontation field test **12**
- Congenital cataract **65**
- Conjunctiva
 - Dry eye syndrome (keratoconjunctivitis sicca) **32**
- Conjunctivitis
 - Allergic **26**
 - Viral **27**
- Corneal abrasion **36**
- Corneal diseases
 - Bacterial keratitis (corneal ulcer) **37**
 - Herpes simplex keratitis **39**
 - Herpes zoster ophthalmicus **44**
- Corticosteroids **197**
- Cover/uncover test **10**
- CRAO (Central retinal artery occlusion) **99, 173**
- CRVO (Central retinal vein occlusion) **102**

D

- Demodex **18**
- Dendritic keratitis **40**
- Diabetic retinopathy **130**
- Discoïd keratitis **41**
- Dry eye syndrome (keratoconjunctivitis sicca) **32**

E

- Endophthalmitis **182**
- Exotropia **162**
- Exudative retinal detachment **128**

F

- Fuchs' heterochromic iridocyclitis (FHI) **47**

G

- Giant-cell arteritis **99, 173**
- Glaucoma
 - Primary angle closure glaucoma **148, 177**
 - Normal tension glaucoma **146**
 - Primary open angle glaucoma **140**

H

- Herpes simplex keratitis **39**
- Herpes zoster ophthalmicus (HZO) **44**
- Hypertension retinopathy **138**

I

- Interstitial keratitis **41**
- Iritis/ iridocyclitis **47**
- Ischemic CRVO **102**

J

- Juvenile rheumatoid arthritis (JRA) **47**

K

- Keratitis
 - Bacterial **37**
 - Herpetic **39**

M

- Macular edema **120**

N

- Nasolacrimal duct obstruction **168**
- Neovascular glaucoma **158**
- Non-ischemic CRVO **102**
- Normal tension glaucoma **146**
- Non-proliferative diabetic retinopathy **130**
- NSAID (non-steroidal anti-inflammatory drugs) **196**

O

- Ocular emergency
 - Chemical burns **171**
 - Central retinal artery occlusion (CRAO) **173**
 - Acute angle closure glaucoma **177**
 - Acute vision loss **211**
- Ocular history **8**
- Optical coherence tomography (OCT) **15**
- Orbital cellulitis **22**

P

- Painless acute vision loss **211**
- Posterior vitreous detachment **91**
- Posterior ischemic optic neuropathy **98**
- Preseptal cellulitis **20**
- Primary open angle glaucoma **140**
- Proliferative diabetic retinopathy **132**
- Pseudoexfoliation syndrome **72**
- PVD (posterior vitreous detachment) **91**

R

- RAPD (relative afferent pupillary defect) **14**
- RD (retinal detachment) **124**
- Retinal artery occlusion **99,173**
- Retinal detachment
 - Rhegmatogenous **125**
 - Tractional **127**
 - Exudative **128**
- Retinal vascular diseases
 - Diabetic retinopathy **130**
 - Hypertension retinopathy **138**
 - Retinal artery occlusion **99**
 - Retinal vein occlusion **102**
- Retinal vein occlusion **102**
- Retinopathy of prematurity (ROP) **154**
- Rhegmatogenous retinal detachment **125**

S

- Sarcoidosis **47**
- Strabismus
 - Esotropia **158**
 - Exotropia **162**
- Acute vision loss **211**
- Sympathetic ophthalmia **62**

T

- Temporal arteritis **99, 173**
- Toxoplasmosis **55**
- Tractional retinal detachment **127**
- Traumatic lens subluxation and dislocation **73**

U

- Uveitis
 - Anterior **47**
 - Posterior **55**

V

- Vein occlusion **102, 107**
- Vernal conjunctivitis **30**
- Viral conjunctivitis **27**
- Vitreous hemorrhage **87**

ANNOTATED RESOURCES

- 1 Agarwal A., Handbook of Ophthalmology, SLACK Incorporated, 2006
- 2 Bakes K., Cadnapaphornchai L., Clinical Assessment of Vision Loss. Emergency Medicine, November 2005, pp.14-24.
- 3 Basic and Clinical Science Course, American Academy of Ophthalmology, 2004-2005
- 4 Bohigian G.M, Valluri S., Ocular Infections, Inflammation and External Diseases, 2000
- 5 Bradford C.A., Basic Ophthalmology, Eighth Edition, 2004
- 6 Chern K.C., Zegans M.E, Ophthalmology Review Manual, 2000
- 7 Color Atlas & Synopsis of Clinical Ophthalmology Wills Eye Hospital. Edited by Rapuano C.J.
- 8 Eye Exam, The Essentials, American Academy of Ophthalmology, 2004
- 9 Friedman N.J., Kaiser P.K., Trattler W.B., Review of Ophthalmology, 2005
- 10 Gold D.H., Lewis R.A., Clinical Eye Atlas, 2002
- 11 Kaiser P.K., Friedman N.J., Pineda R. The Massachusetts Eye and Ear Infirmary Illustrated Manual of Ophthalmology, Second Edition, 2004
- 12 Kanski J.J., Clinical Ophthalmology. A Systematic Approach. Fifth Edition, 2003
- 13 Kunimoto D.Y., Kanitkar K.D., Makar M.S. The Wills Eye Manual, Office and Emergency Room Diagnosis and Treatment of Eye Disease. Fourth Edition, 2004
- 14 Mandava S., Sweency T., Guyer D. Color Atlas of Ophthalmology, 1999
- 15 The Merck Manual of Diagnosis and Therapy, 2004, Section 8 Ophthalmologic Disorders
- 16 Roberts, C.M., Quick Consult to Diagnosing and Treating Ocular Disease, 2002
- 17 Spalton D.J., Hitchings R.A., Hunter P.A., Atlas of Clinical Ophthalmology, Third Edition, 2005
- 18 Rohit Varma, Essentials of Eye Care, 1997
- 19 Vrabec M.P., Florakis G.J., Ophthalmic Essentials, 1992
- 20 Fred M. Wilson II. Practical Ophthalmology, Fourth Edition, 1996